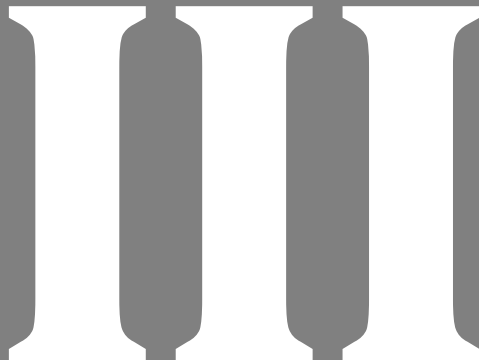


**Part III**  
**Imaging and Diagnostics**

<b>12 Plain Radiology and Contrast Agents</b>	<b>51</b>
<b>13 Imaging and Angiography</b>	<b>54</b>
<b>14 Electrodiagnostics</b>	<b>58</b>





## 12 Plain Radiology and Contrast Agents

### Questions

#### ►► Question 1

Which of the following marks the anterior limit of spinal canal?

- A. Anterior marginal line
- B. Middle marginal line
- C. Posterior marginal line
- D. Posterior spinal line
- E. Spinolaminar line

#### ►► Question 2

What is the average normal anterior dentate interval in adult male?

- A. < 3 mm
- B. 7 mm
- C. 9 mm
- D. 11 mm
- E. 15 mm

#### ►► Question 3

On cervical spine anteroposterior X-ray, a fracture-dislocation or ligament disruption may be diagnosed if the interspinous distance (measured from center of spinous processes) relative to that at both adjacent levels is what?

- A. 0.25 times
- B. 0.5 times
- C. Equal
- D. > 1.5 times
- E. Not related

#### ►► Question 4

In C2 vertebra, how many primary ossification centers are there at birth?

- A. 1
- B. 2
- C. 3
- D. 4
- E. 5

#### ►► Question 5

Butterfly vertebra is an uncommon congenital anomaly thought to arise from failure of fusion of the lateral halves of the vertebral bodies due to persistent notochord tissue on AP X-rays or coronal CT scan reconstructions. On lateral views, what may it mimic?

- A. Locked facets
- B. Burst fracture

- C. Compression fracture
- D. Fracture dislocation
- E. Teardrop fracture

#### ►► Question 6

For basilar invagination, what is the line drawn across foramen magnum (basion to opisthion)?

- A. McRae's line
- B. Chamberlain's line
- C. McGregor's baseline
- D. Wackenheim's clivus-canal line
- E. Fischgold's digastric line

#### ►► Question 7

For basilar invagination, posterior hard palate to posterior margin of foramen magnum-opisthion is what?

- A. McRae's line
- B. Chamberlain's line
- C. McGregor's baseline
- D. Wackenheim's clivus-canal line
- E. Fischgold's digastric line

#### ►► Question 8

What is the primary approved contrast agent for intrathecal use?

- A. Iohexol
- B. Iopromide
- C. Ioversol
- D. Iodixanol
- E. Ultravist

#### ►► Question 9

What is the U.S. Nuclear Regulatory Commission (NRC) recommended maximal annual occupational dose limits for radiation (rem/y) for whole body?

- A. 5
- B. 10
- C. 15
- D. 20
- E. 50

#### ►► Question 10

For minimizing the occupational radiation exposure, ALARA ("As Low As Reasonably Achievable") involves making every reasonable effort to keep radiation dose as far below the limits as possible and it is believed that lead aprons and shields may or may not work, but distance always works. What distance (ft) the American Association of Neurological Surgeons (AANS) has recommended to be kept?

- A. 1
- B. 2
- C. 3
- D. 5
- E. 10

►► Question 11

On lateral c spine X-ray, there are four contour lines which normally form smooth gentle curve. Which of these four lines forms the anterior margin of spinal canal?

- A. Anterior marginal line along the anterior cortical surface
- B. Posterior marginal line along the posterior cortical surface
- C. Spinolaminar line
- D. Posterior spinous line
- E. None of above

►► Question 12

According to the rule of Spence, the transverse atlantal ligament (TAL) is probably disrupted if the sum total overhang of both C1 lateral masses over C2 is more than or equal to what?

- A. 3 cm
- B. 5 cm
- C. 7 cm
- D. 9 cm
- E. 11 cm

►► Question 13

Posterior atlantodental interval, which is the distance from the back of odontoid to the anterior aspect of posterior C1 arch, forms the spinal canal diameter at this level. Stenosis of cervical spinal canal is present if the canal diameter is less than what?

- A. 10 mm
- B. 11 mm
- C. 12 mm
- D. 13 mm
- E. 15 mm

►► Question 14

Which of the following statements is true?

- A. On oblique X-ray view of lumbar sacral spine, discontinuation in the neck of scotty dog shows defect of spinous process
- B. AP X-ray view of lumbar sacral spine: nonvisualization of owl's eyes shows pedicle erosion which is due to lytic tumor
- C. Butterfly vertebra is due to failure of fusion of two halves of posterior vertebral arches
- D. In axis vertebrae, the anterior synchondroses normally fuse between 6 and 9 years of age
- E. All of the above statements are correct

►► Question 15

The depth and length of the sella turcica on lateral view of normal skull X-ray are 8.1 and 10.6 mm, respectively. How

does pituitary adenoma changes the dimensions of sella turcica?

- A. It tends to enlarge the sella
- B. It erodes posterior clinoids and does not enlarge sella
- C. It balloons the sella symmetrically
- D. It does not enlarge sella but causes enlargement of sphenoid sinus
- E. None of the above

►► Question 16

Basilar invagination/basilar impression (BI) is upward displacement of odontoid process through foramen magnum into the posterior fossa. Which of the following is best statement regarding BI?

- A. Basilar impression implies abnormal softening of skull base bones with atlantooccipital fusion
- B. Basilar invagination means normal skull base bones
- C. Platybasia is abnormal basal angle at skull base with > 145 degrees angle
- D. Type 1 BI means BI with Chiari malformation
- E. Type 2 BI denotes BI without Chiari malformation

►► Question 17

McRae's line is drawn from basion to opisthion and it is used in measurements in basilar invagination (BI). What is the relationship of odontoid tip with this line for excluding the diagnosis of BI?

- A. No part of odontoid tip should be above this line
- B. Dens should not be more than 3 mm above this line
- C. Dens should not be more than 4.5 mm above this line
- D. Odontoid tip should be 3 mm below this line
- E. None of the above

►► Question 18

Which of the following conditions are associated with basilar invagination (BI)?

- A. Congenital conditions like Down syndrome, Klippel-Feil syndrome, Chiari malformation, or syringomyelia
- B. Acquired conditions like rheumatoid arthritis
- C. Post-traumatic
- D. Conditions with softening of bone like Paget's disease, osteogenesis imperfecta, osteomalacia, rickets, or hyperparathyroidism
- E. All of the above

►► Question 19

What medication can be used in a patient going to use intravenous contrast agent with previous history of mild reaction with iodinated contrast medium for prevention of reaction again?

- A. Prednisone 50 mg po
- B. Solumedrol 25 mg IV

- C. Diphenhydramine 50 mg IM
- D. Hydrocortisone 100 mg IV
- E. All of the above

## Answers

### ▶▶ Answer 1

Correct answer is C. Posterior marginal line<sup>1</sup>

### ▶▶ Answer 2

Correct answer is A. < 3 mm<sup>2</sup>

### ▶▶ Answer 3

Correct answer is D. > 1.5 times<sup>3</sup>

### ▶▶ Answer 4

Correct answer is D. 4<sup>4</sup>

### ▶▶ Answer 5

Correct answer is C. Compression fracture<sup>5</sup>

### ▶▶ Answer 6

Correct answer is A. McRae's line<sup>6</sup>

### ▶▶ Answer 7

Correct answer is B. Chamberlain's line<sup>6</sup>

### ▶▶ Answer 8

Correct answer is A. Iohexol<sup>7</sup>

### ▶▶ Answer 9

Correct answer is A. 5<sup>8</sup>

### ▶▶ Answer 10

Correct answer is E. 10<sup>8</sup>

### ▶▶ Answer 11

Correct answer is B. Posterior marginal line along the posterior cortical surface<sup>1</sup>

### ▶▶ Answer 12

Correct answer is C. 7 cm<sup>2</sup>

### ▶▶ Answer 13

Correct answer is C. 12 mm<sup>3</sup>

### ▶▶ Answer 14

Correct answer is B. AP X-ray view of lumbar sacral spine: nonvisualization of owl's eyes shows pedicle erosion which is due to lytic tumor<sup>4</sup>

### ▶▶ Answer 15

Correct answer is A. It tends to enlarge the sella<sup>5</sup>

### ▶▶ Answer 16

Correct answer is C. Platybasia is abnormal basal angle at skull base with > 145 degrees angle<sup>6</sup>

### ▶▶ Answer 17

Correct answer is A. No part of odontoid tip should be above this line<sup>6</sup>

### ▶▶ Answer 18

Correct answer is E. All of the above<sup>9</sup>

### ▶▶ Answer 19

Correct answer is E. All of the above<sup>10</sup>

## References

- [1] Greenberg M, ed. Greenberg's Handbook of Neurosurgery. 10th ed. New York: Thieme; 2023:222
- [2] Greenberg M, ed. Greenberg's Handbook of Neurosurgery. 10th ed. New York: Thieme; 2023:223
- [3] Greenberg M, ed. Greenberg's Handbook of Neurosurgery. 10th ed. New York: Thieme; 2023:224
- [4] Greenberg M, ed. Greenberg's Handbook of Neurosurgery. 10th ed. New York: Thieme; 2023:226
- [5] Greenberg M, ed. Greenberg's Handbook of Neurosurgery. 10th ed. New York: Thieme; 2023:227
- [6] Greenberg M, ed. Greenberg's Handbook of Neurosurgery. 10th ed. New York: Thieme; 2023:228
- [7] Greenberg M, ed. Greenberg's Handbook of Neurosurgery. 10th ed. New York: Thieme; 2023:230
- [8] Greenberg M, ed. Greenberg's Handbook of Neurosurgery. 10th ed. New York: Thieme; 2023:235
- [9] Greenberg M, ed. Greenberg's Handbook of Neurosurgery. 10th ed. New York: Thieme; 2023:229
- [10] Greenberg M, ed. Greenberg's Handbook of Neurosurgery. 10th ed. New York: Thieme; 2023:232

## 13 Imaging and Angiography

### Questions

#### ►► Question 1

Originally, axial CT scan slices were taken parallel to the orbitomeatal line which connects the lateral canthus of the eye to the midpoint of the external auditory meatus. Current volumetric CT scanners tend to create axial slices parallel to what?

- A. McRae's line
- B. Chamberlain's line
- C. AC-PC line
- D. McGregor's baseline
- E. Wackenheim's clivus-canal line

#### ►► Question 2

A noncontrast CT scan is usually employed in emergency situations for diagnosis and screening. However, diffusion-weighted (DWI) MRI is preferred in which of the following?

- A. Acute stroke
- B. Subarachnoid hemorrhage
- C. Intraparenchymal hemorrhage
- D. Acute subdural hemorrhage
- E. Pneumocephalus

#### ►► Question 3

For CT perfusion to assess cerebral blood volume and flow, which of the following tests is used?

- A. Acetazolamide challenge test
- B. Dexamethasone challenge test
- C. Insulin tolerance test
- D. Oral glucose tolerance test
- E. Water deprivation

#### ►► Question 4

In fluid-attenuated inversion recovery (FLAIR), the gray/white intensity pattern is reversed from T1WI and it resembles a T2WI except the CSF which is more what?

- A. Bright
- B. Hyperintense
- C. Same density
- D. Dark
- E. White

#### ►► Question 5

Regarding gradient echo MRI, which of the following appears white?

- A. Bone
- B. Calcium

- C. Heavy metals
- D. Intraparenchymal blood
- E. CSF

#### ►► Question 6

Which of the following is the most sensitive study for ischemia of the brain?

- A. DWI MRI
- B. Fluid-attenuated inversion recovery (FLAIR)
- C. Perfusion-weighted (PWI) MRI
- D. CT of brain with intrathecal contrast
- E. EEG

#### ►► Question 7

Regarding peaks on magnetic resonance spectroscopy (MRS), which of the following is the marker of membrane synthesis?

- A. Lipid
- B. Acetate
- C. Creatinine
- D. Choline
- E. N-acetyl aspartate

#### ►► Question 8

Which of the following is the most useful to permit planning surgical approaches that minimize disruption of critical white matter tracts during brain surgery for deep lesions?

- A. DWI MRI
- B. Fluid-attenuated inversion recovery (FLAIR)
- C. PWI MRI
- D. Diffusion tensor imaging (DTI) MRI
- E. Proton magnetic resonance spectroscopy (MRS)

#### ►► Question 9

Usual convention for color coding tracts on diffusion tensor imaging (DTI). Superior longitudinal fasciculus is colored what?

- A. Red
- B. Blue
- C. Green
- D. White
- E. Black

#### ►► Question 10

Three-phase bone scan uses technetium 99m-HDP and has three phases: flow phase, blood pooling, and bone imaging. Osteomyelitis causes increased uptake in which phase?

- A. 1st phase
- B. 2nd phase
- C. 3rd phase
- D. All three phases
- E. No intake

►► **Question 11**

Attenuation of the X-ray beam on a CT scan is quantified in Hounsfield units. What are the Hounsfield units for air and dense bone, respectively?

- A. + 1000, -1000
- B. -1000, + 1000
- C. -100, + 100
- D. + 5, -5
- E. 0, + 1000

►► **Question 12**

CT perfusion (CTP) uses iodinated contrast (40 mL IV at 5 mL/sec) in which scans are repeated through region of interest at small intervals. Acetazolamide challenge is given (1000 mg IV) and scans are repeated at intervals again. Which of the following parameters can be calculated by this method?

- A. Cerebral blood volume
- B. Cerebral blood flow
- C. Mean transit time
- D. Time to peak
- E. All of the above

►► **Question 13**

The radiation dose to a fetus from head or cervical spine CT is small and can be reduced by lead shielding. The risk from fetal exposure to X-rays is highest during which time of pregnancy?

- A. The first 2 weeks of gestation
- B. Between 8 and 16 weeks of gestation
- C. In the first 3 months of gestation
- D. In the 4th and 5th months of gestation
- E. Both A and B

►► **Question 14**

Following statements are correct regarding T1WI MRI except?

- A. Fat including bone marrow, blood > 48 hours old, and melanin appears bright
- B. CSF and bone appear dark
- C. Anatomic image which somewhat resembles CT
- D. Most pathology is high signal
- E. White matter has higher signal than gray matter

►► **Question 15**

Which of the following statements are true regarding T2WI MRI images?

- A. Most pathology shows up as high signal including surrounding edema
- B. Brain edema, water, and fat appear bright
- C. Bone appears dark
- D. Clues to recognize are CSF is white, long TR and TE
- E. Fluid-attenuated inversion recovery (FLAIR) resembles T2WI except that CSF is nulled out (appears dark)
- F. All of the above

►► **Question 16**

Following statements are correct except?

- A. GRASS (gradient recalled acquisition in a steady state) MRI images are useful for visualizing myelographic cervical spine image, bony spurs, and small old cerebral blood
- B. STIR (short tau inversion recovery) is a fat suppression image which is good to visualize bone edema, periventricular lesion, or intraorbital fat
- C. FIESTA (fast imaging employing steady state acquisition) is useful to visualize pathology at cerebellopontine angle
- D. CISS (constructive interference in steady state) is useful for imaging cranial nerves, CSF leaks, and aqueductal stenosis
- E. Gradient echo images also known as T2 GRE images are useful for seeing brainstem lesions

►► **Question 17**

MRI with pituitary protocol is used to visualize pituitary gland with detailed imaging. It has all of the following components except?

- A. MRI is done without contrast
- B. Thin coronal cuts are taken through sella, cavernous sinus, and optic chiasma
- C. Dynamic images at intervals are taken to differentiate adenoma from pituitary as pituitary enhances before adenoma
- D. Microadenomas can be visualized using this method
- E. It is done by using MRI with and without contrast

►► **Question 18**

All of the following are common contraindications to MRI except?

- A. Cardiac pacemakers, defibrillators, implanted neurostimulators, cochlear implants, and infusion pumps
- B. Nonferromagnetic aneurysm clips
- C. Ferromagnetic aneurysm clips
- D. Metallic implants or foreign bodies with iron in it
- E. Placement of vascular stents, coil, filter within past 6 weeks

►► **Question 19**

Intraparenchymal areas of bright signal on DWI that are not bright on apparent diffusion coefficient (ADC) map are abnormal and represent regions of restricted diffusion. It is useful in the diagnosis of which of the following pathologies in brain?

- A. Ischemic brain tissue
- B. Cerebral abscess
- C. Active MS plaques
- D. Some tumors like epidermoids, lymphoma, or some meningiomas
- E. All of the above

►► Question 20

All of the following are true regarding magnetic resonance spectroscopy (MRS) except?

- A. Lactate is a marker of hypoxia and indicates ischemia, infection, or demyelinating disease
- B. N-acetyl aspartate (NAA) is decreased in brain tumor, MS, brain abscess, and brain injury
- C. Choline is increased in brain neoplasms
- D. Abscess causes decreased succinate and acetate peaks
- E. Tumor causes increased lactate, lipid, choline, and decreased NAA

►► Question 21

Diffusion tensor imaging also known as diffusion tensor tractography is an MRI technique that demonstrates white matter tracts in brain. Surgical trajectory is kept parallel to the long axis of white matter tract to avoid its damage. What are the fibers that connect regions within the same hemisphere?

- A. Optic radiations
- B. Uncinate fasciculus
- C. Arcuate fasciculus
- D. Cingulum
- E. All of the above

►► Question 22

All of the following are the contraindications to myelography except?

- A. Anticoagulation
- B. Allergy to iodinated contrast
- C. Obese patient
- D. Infection at desired puncture site
- E. Extensive midline lumbar spinal fusion

►► Question 23

Technetium-99 is a radioisotope that may be attached to various substrates for use in bone scan. Bone scan can be used to aid in the diagnosis of which of the following?

- A. Bone infections
- B. Bony tumor
- C. Craniosynostosis
- D. Fracture
- E. All of the above

## Answers

►► Answer 1

Correct answer is C. AC-PC line<sup>1</sup>

►► Answer 2

Correct answer is A. Acute stroke<sup>1</sup>

►► Answer 3

Correct answer is A. Acetazolamide challenge test<sup>2</sup>

►► Answer 4

Correct answer is D. Dark<sup>3</sup>

►► Answer 5

Correct answer is E. CSF<sup>4</sup>

►► Answer 6

Correct answer is C. Perfusion-weighted (PWI) MRI<sup>5</sup>

►► Answer 7

Correct answer is D. Choline<sup>5</sup>

►► Answer 8

Correct answer is D. Diffusion tensor imaging (DTI) MRI<sup>6</sup>

►► Answer 9

Correct answer is C. Green<sup>7</sup>

►► Answer 10

Correct answer is D. All three phases<sup>8</sup>

►► Answer 11

Correct answer is B. -1000, +1000<sup>1</sup>

►► Answer 12

Correct answer is E. All of the above<sup>2</sup>

►► Answer 13

Correct answer is E. Both A and B<sup>2</sup>

►► Answer 14

Correct answer is D. Most pathology is high signal<sup>2</sup>



## ▶▶ Answer 15

Correct answer is F. All of the above<sup>3</sup>

## ▶▶ Answer 16

Correct answer is E. Gradient echo images also known as T2 GRE images are useful for seeing brainstem lesions<sup>4</sup>

## ▶▶ Answer 17

Correct answer is A. MRI is done without contrast<sup>4</sup>

## ▶▶ Answer 18

Correct answer is B. Nonferromagnetic aneurysm clips<sup>9</sup>

## ▶▶ Answer 19

Correct answer is E. All of the above<sup>10</sup>

## ▶▶ Answer 20

Correct answer is D. Abscess causes decreased succinate and acetate peaks<sup>5</sup>

## ▶▶ Answer 21

Correct answer is E. All of the above<sup>6</sup>

## ▶▶ Answer 22

Correct answer is C. Obese patient<sup>8</sup>

## ▶▶ Answer 23

Correct answer is E. All of the above<sup>8</sup>

## References

- [1] Greenberg M, ed. Greenberg's Handbook of Neurosurgery. 10th ed. New York: Thieme; 2023:238
- [2] Greenberg M, ed. Greenberg's Handbook of Neurosurgery. 10th ed. New York: Thieme; 2023:239
- [3] Greenberg M, ed. Greenberg's Handbook of Neurosurgery. 10th ed. New York: Thieme; 2023:240
- [4] Greenberg M, ed. Greenberg's Handbook of Neurosurgery. 10th ed. New York: Thieme; 2023:241
- [5] Greenberg M, ed. Greenberg's Handbook of Neurosurgery. 10th ed. New York: Thieme; 2023:244
- [6] Greenberg M, ed. Greenberg's Handbook of Neurosurgery. 10th ed. New York: Thieme; 2023:245
- [7] Greenberg M, ed. Greenberg's Handbook of Neurosurgery. 10th ed. New York: Thieme; 2023:246
- [8] Greenberg M, ed. Greenberg's Handbook of Neurosurgery. 10th ed. New York: Thieme; 2023:247
- [9] Greenberg M, ed. Greenberg's Handbook of Neurosurgery. 10th ed. New York: Thieme; 2023:242
- [10] Greenberg M, ed. Greenberg's Handbook of Neurosurgery. 10th ed. New York: Thieme; 2023:243

## 14 Electrodiagnostics

### Questions

#### ►► Question 1

Bilateral periodic lateralizing epileptiform discharges (PLEDs) on EEG is diagnostic of which of the following?

- A. Creutzfeldt-Jakob disease
- B. Anoxic encephalopathy
- C. Brain death
- D. Herpes simplex encephalitis
- E. Bacterial meningitis

#### ►► Question 2

Regarding common EEG rhythms, a frequency of > 13 Hz is what?

- A. Alpha
- B. Beta
- C. Theta
- D. Delta
- E. Epsilon

#### ►► Question 3

Regarding brainstem auditory evoked responses (BAER), vestibular schwannoma may be suggested by which of the following?

- A. I peak latency
- B. I-III peak latency
- C. V peak latency
- D. N9-N18 peak latency
- E. P100 absolute latency

#### ►► Question 4

Regarding cervical electromyography (EMG), there are no good muscles to reliably test which of the following?

- A. C4
- B. C5
- C. C6
- D. C7
- E. C8

#### ►► Question 5

Reduction of sensory nerve action potential (SNAP) with no paraspinal muscle fibrillations suggests which of the following?

- A. Monoradiculopathy
- B. Plexopathy
- C. Traumatic herniated lumbar disk
- D. Transverse myelitis
- E. Motor neuron disease

#### ►► Question 6

The primary use of electroencephalogram (EEG) is the diagnosis and management of seizure disorder. Following statements regarding differential diagnosis on the basis of EEG pattern are correct except?

- A. Herpes simplex encephalitis causes periodic lateralizing epileptiform discharges on EEG
- B. Subacute sclerosing panencephalitis causes periodic high voltage with 4 to 15 seconds separation
- C. Creutzfeldt-Jakob disease causes bilateral sharp waves 1.5 to 2 per second
- D. Cannot differentiate between hydranencephaly and severe hydrocephalus
- E. Used as a clinical confirmation test in the determination of brain death

#### ►► Question 7

Somatosensory evoked potential (SSEP) and brain stem auditory evoked potential (BAER) are used by neurosurgeons for intraoperative monitoring purposes. What should cause the surgeon to assess all variables (retractors, instruments, blood pressure) and do surgery more carefully?

- A. A 10% increased latency of a major evoked potential peak
- B. A drop in amplitude of more than or equal to 50%
- C. Complete loss of waveform
- D. Increase in 50% latency
- E. A, B, and C

#### ►► Question 8

Impulses during somatosensory evoked potential monitoring during spine surgery are carried through which tract of spinal cord?

- A. Spinothalamic tract
- B. Ipsilateral posterior column
- C. Dorsolateral fasciculus
- D. Both B and C
- E. Spinocerebellar tract

#### ►► Question 9

Transcranial motor evoked potentials (TCMEPs) are generated by stimulation of motor cortex of brain or descending axons in spinal cord using EMG recordings of motor potentials from representative muscle groups. What is the contraindication of using TCMEP?

- A. History of epilepsy or seizures
- B. Past surgical skull defects
- C. Metal in head or neck
- D. Implanted electronic devices
- E. All of the above

## ▶▶ Question 10

Following statements regarding checklist for changes in SSEP or TCMEPs during spine surgery are correct except?

- A. Technical defect in recording such as connections or electrodes position
- B. Pause the surgery and eliminate possible distractions
- C. Stagnara wake up test is not useful in this situation
- D. Metabolic considerations such as anemia, mean arterial pressure, change in pH, body temperature
- E. Patient positions, retractors, instruments

## ▶▶ Question 11

Nerve conduction study (NCS) (nerve conduction velocity) is performed by applying electrical stimulation through surface electrodes at specified location, and electrical stimulation is recorded at receiving electrodes. Which of the following components of a nerve can be studied using NCS?

- A. Nerve conduction velocity
- B. Amplitude of nerve
- C. Latency
- D. Duration of motor and sensory nerves
- E. All of the above

## ▶▶ Question 12

All of the following are the components of electromyographic study except?

- A. Sensory nerve action potential (SNAP)
- B. F-wave
- C. B-wave
- D. H-reflex
- E. Polyphasic potentials

## ▶▶ Question 13

An EMG examination has three phases: insertional activity, spontaneous activity, and volitional activity. Which of the following are potentials or discharges that are observed in nerve disorders?

- A. Fibrillation potentials that are observed in lower motor neuron death or denervation
- B. Complex repetitive discharges that are seen in neuropathic or myopathic disorders
- C. Fasciculation potentials that are seen in motor neuron disease
- D. Motor unit action potential analysis in which change in amplitude or duration of nerve action potential shows disorder of LMN or myopathic disorder
- E. All of the above

## ▶▶ Question 14

What are the EMG criteria for radiculopathy?

- A. Fibrillation potential or positive sharp waves in at least two muscles innervated by a single nerve root in question, with single peripheral nerve
- B. Fibrillation potential or positive sharp waves in at least two muscles innervated by a single nerve root in question but by two different peripheral nerves
- C. Fibrillation potential or positive sharp waves in two muscles innervated by two nerve roots with two different peripheral nerves
- D. Fibrillation potential in muscles irrespective of nerve root in question
- E. None of above

## ▶▶ Question 15

On healing radiculopathy, which potential return first on EMG?

- A. Sensory potential
- B. Motor potential
- C. Fibrillation potential
- D. Fasciculation potential
- E. Positive sharp waves

## Answers

## ▶▶ Answer 1

Correct answer is D. Herpes simplex encephalitis<sup>1</sup>

## ▶▶ Answer 2

Correct answer is B. Beta<sup>1</sup>

## ▶▶ Answer 3

Correct answer is B. I-III peak latency<sup>2</sup>

## ▶▶ Answer 4

Correct answer is A. C4<sup>3</sup>

## ▶▶ Answer 5

Correct answer is B. Plexopathy<sup>4</sup>

## ▶▶ Answer 6

Correct answer is D. Cannot differentiate between hydranencephaly and severe hydrocephalus<sup>1</sup>

## ▶▶ Answer 7

Correct answer is E. A, B, and C<sup>5</sup>

## ▶▶ Answer 8

Correct answer is D. Both B and C<sup>2</sup>

►► Answer 9

Correct answer is E. All of the above<sup>6</sup>

►► Answer 10

Correct answer is C. Stagnara wake up test is not useful in this situation<sup>5</sup>

►► Answer 11

Correct answer is E. All of the above<sup>5</sup>

►► Answer 12

Correct answer is C. B-wave<sup>7</sup>

►► Answer 13

Correct answer is E. All of the above<sup>7</sup>

►► Answer 14

Correct answer is B. Fibrillation potential or positive sharp waves in at least two muscles innervated by a single nerve root in question but by two different peripheral nerves<sup>3</sup>

►► Answer 15

Correct answer is B. Motor potential<sup>4</sup>

## References

- [1] Greenberg M, ed. Greenberg's Handbook of Neurosurgery. 10th ed. New York: Thieme; 2023:249
- [2] Greenberg M, ed. Greenberg's Handbook of Neurosurgery. 10th ed. New York: Thieme; 2023:252
- [3] Greenberg M, ed. Greenberg's Handbook of Neurosurgery. 10th ed. New York: Thieme; 2023:256
- [4] Greenberg M, ed. Greenberg's Handbook of Neurosurgery. 10th ed. New York: Thieme; 2023:257
- [5] Greenberg M, ed. Greenberg's Handbook of Neurosurgery. 10th ed. New York: Thieme; 2023:254
- [6] Greenberg M, ed. Greenberg's Handbook of Neurosurgery. 10th ed. New York: Thieme; 2023:253
- [7] Greenberg M, ed. Greenberg's Handbook of Neurosurgery. 10th ed. New York: Thieme; 2023:255