

# 9 The Uveal Tract

Anatomy and Physiology .....	222
Inflammation (Uveitis) (OP6.1, 6.2, 6.3, 6.8).....	226
Anterior Uveitis (Iridocyclitis) (OP6.1, 6.2, 6.3, 6.8) (OP6.6) .....	229
Intermediate Uveitis (Pars Planitis).....	239
Posterior Uveitis .....	240
Specific Types of Uveitis.....	243
Endophthalmitis.....	256
Panophthalmitis .....	259
Pigment Dispersion Syndrome .....	260
Degenerative Changes in Uveal Tract.....	260
Detachment of Choroid .....	263
Congenital Anomalies of Uveal Tract .....	264

## Anatomy and Physiology

Uveal tract is the middle and highly vascular coat of eyeball. It consists of the following three parts: iris, ciliary body, and choroid.

**Iris** is the anterior most part of the uveal tract. **Ciliary body** extends from the scleral spur anteriorly up to ora serrata posteriorly. **Choroid** extends from the ora serrata anteriorly up to optic disc posteriorly. Ciliary body and choroid line the sclera. These anatomically distinct parts of the uveal tract are closely related; hence, the inflammatory processes affecting one part often involve the other part too.

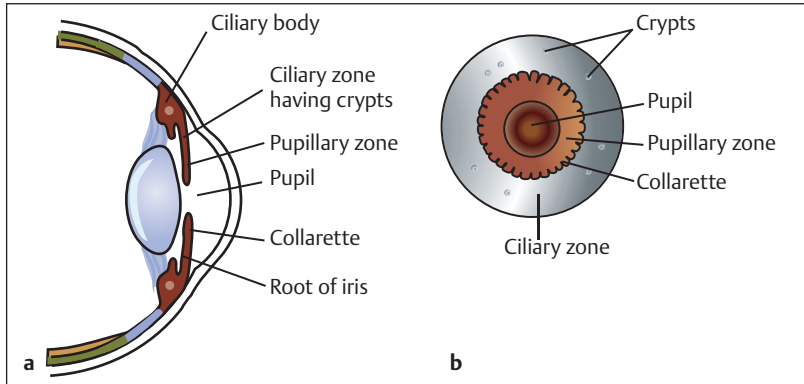
### Iris

It forms a free circular diaphragm in the coronal plane which contains an aperture in the center called **pupil** (diameter 2.5–4 mm). The iris is attached with the ciliary body. This attachment is

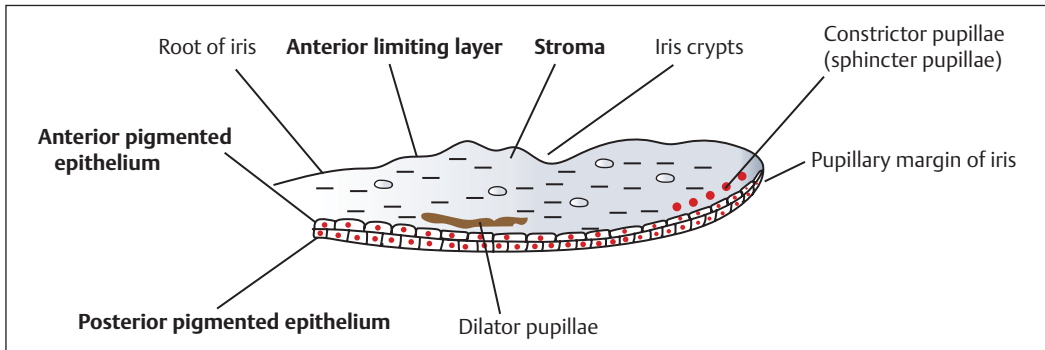
called **root**. The root is the thinnest part; hence, prone to tear on trauma. **Collarette** divides the anterior surface of iris into the pupillary and ciliary zones. **Crypts** (minute depressions) are mainly found in the ciliary zone (**Fig. 9.1**).

**Microscopically**, iris is composed of four layers (anterior to posterior, **Fig. 9.2**):

- **Anterior limiting layer:** It covers the anterior surface of the iris and is deficient in areas of crypts; this allows easy transfer of fluid between iris and anterior chamber.
- **Iris stroma:** It consists of loosely arranged collagenous network and also contains:
  - ◇ Blood vessels which run in a radial direction.
  - ◇ Nerves.
  - ◇ Pigment cells.
  - ◇ Two unstripped muscles: Sphincter pupillae and dilator pupillae (**Fig. 9.3** and **Table 9.1**).



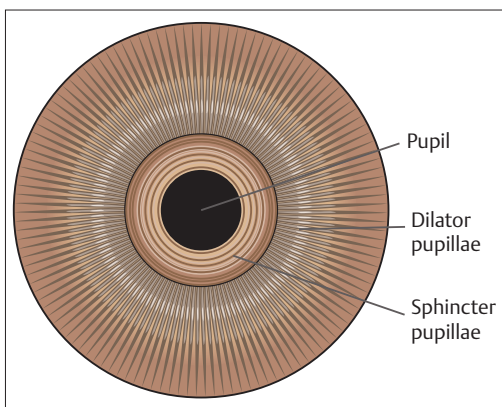
**Fig. 9.1 (a, b)** Anterior surface of iris.



**Fig. 9.2** Microscopic structure of iris. (AN41.3).

**Table 9.1** Differentiating features of muscles of iris stroma (AN41.3)

Features	Sphincter pupillae	Dilator pupillae
Fibers	Fibers are circular around pupillary margin.	Fibers are arranged radially near the root of iris.
Nerve supply	Parasympathetic fibers via oculomotor (IIIrd) nerve.	By cervical sympathetic nerves.
Function	Constriction of pupil ( <b>miosis</b> ).	Dilatation of pupil ( <b>mydriasis</b> ).



**Fig. 9.3** Unstriated muscles of iris stroma. (AN41.3).

- *Anterior pigmented epithelium* consists of flattened cells.
- *Posterior pigmented epithelium* consists of cuboidal cells. These two layers of pigmented epithelium, developmentally, are derived from retina and are continuous with each other at the pupillary margin.

The sensory nerve supply of the iris is derived from the trigeminal (Vth) nerve.

### Ciliary Body

It is triangular in cross-section with the base forward. The iris is attached at the middle of

the base, so the base forms part of the angle of the anterior and posterior chambers. The **outer surface** of the ciliary body lies against the sclera. The **stroma** of the ciliary body is composed of collagen fibers as well as ciliary muscle, vessels, and nerves. The **inner surface** of the ciliary body is divided into two regions:

**Anterior part:** It is called **pars plicata** and has ~40 villi which form ridges around the circumference which are known as *ciliary processes*.

**Posterior part:** It is smooth and called **pars plana** (Fig. 9.4).

### Ciliary Processes

The core of ciliary processes contains blood vessels embedded in loose connective tissue. These are the **site of aqueous production**. The inner surface is lined by epithelium which is two layered (Fig. 9.5):

**Outer pigmented layer:** It is a continuation of the retinal pigment epithelium; in forward direction, it is continuous with anterior pigmented epithelium of iris.

**Inner nonpigmented layer:** It represents forward continuation of sensory retina and is continuous with posterior pigmented epithelium of iris.

### Ciliary Muscle (AN41.3)

It is an unstriated muscle and forms the chief mass of the ciliary body. Ciliary processes contain no part of the ciliary muscle. It is composed of three types of fibers with a common origin.

1. **Meridional (longitudinal) fibers:** These are inserted at the scleral spur and run anteroposteriorly on the inner aspect of sclera. These are involved in regulation of aqueous outflow.
2. **Radial (oblique) fibers:** These are inserted in the root of iris in close relation to the dilator muscle.
3. **Circular fibers:** These help in accommodation.

**Nerve supply** of ciliary muscle: It is supplied by the oculomotor nerve (through short ciliary nerves). Its *sensory nerve supply* is derived from the trigeminal (Vth) nerve.

### Functions of Ciliary Body

The ciliary body serves the following functions:

- Formation of aqueous humor (by ciliary processes).
- Accommodation (through circular fibers of the ciliary muscle).

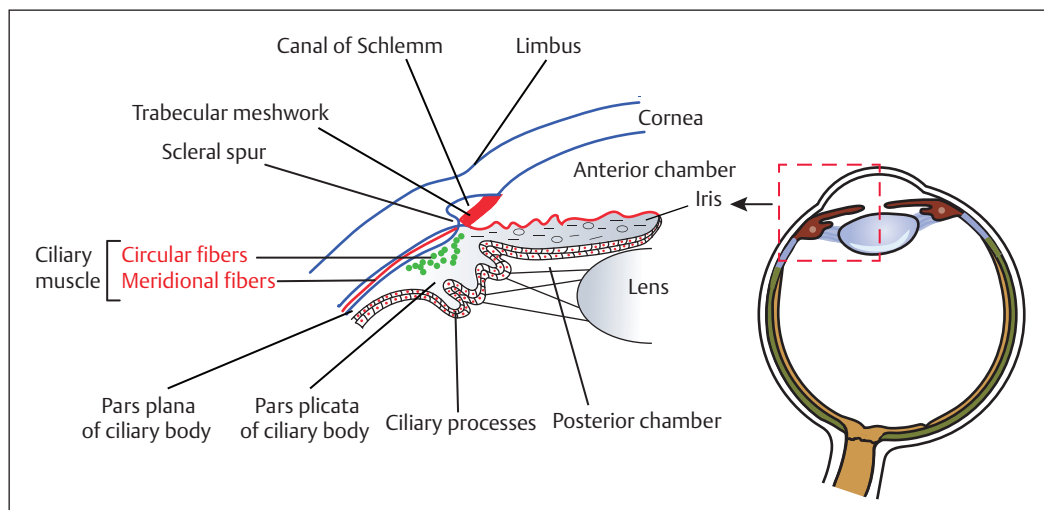


Fig. 9.4 Parts of ciliary body. (AN41.3).

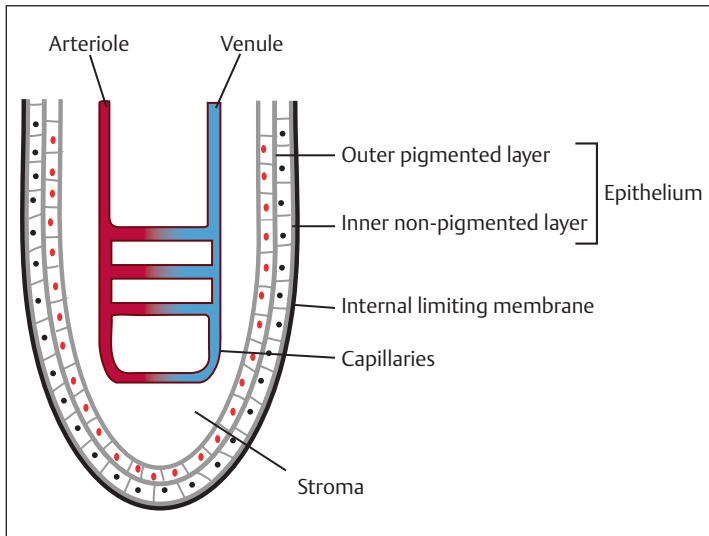


Fig. 9.5 Layers of ciliary processes.

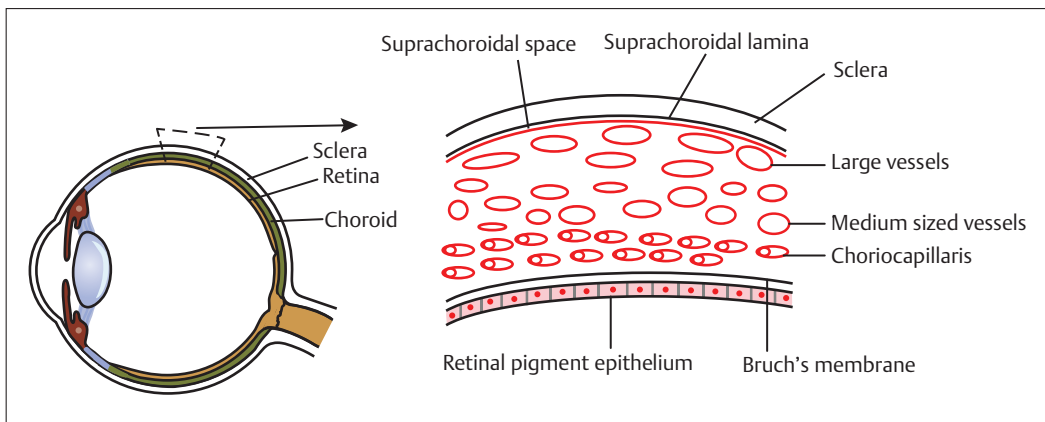


Fig. 9.6 Microscopic structure of choroid.

- Regulation of aqueous outflow (through insertion of the meridional fibers of ciliary muscle at the scleral spur).

### Choroid

It is an extremely vascular part of the uveal tract. Outer surfaces (suprachoroidal lamina) lie in contact with sclera, with a potential space between the two structures, the **suprachoroidal space**, which contains long and short posterior ciliary arteries and nerves. The inner surface is in contact with **Bruch's membrane**, a thin elastic

membrane. The stroma of choroid is largely composed of blood vessels which increase in size from within outward. Thus, the innermost (immediately beneath Bruch's membrane) zone comprises ciliary plexus formed by fenestrated vessels called **choriocapillaris** which nourish the outer layer of retina (Fig. 9.6).

**Nerve supply** of choroid: The sensory fibers are derived from the trigeminal (V) nerve, and the vasomotor function is regulated by autonomic nerves (Table 9.2).

**Table 9.2** Nerve supply of uveal tract

Sensory nerve supply	Trigeminal (V) nerve
<b>Motor</b> nerve supply:	
• Sphincter pupillae and ciliary muscle	• <b>Oculomotor (III) nerve</b> (parasympathetic nerve fibers)
• Dilator pupillae	• <b>Cervical sympathetic nerves</b>
<b>Vasomotor</b> function	Regulated by <b>autonomic nerves</b>

## Blood Supply of Uveal Tract

**Arterial supply:** Uveal tract is supplied by three groups of ciliary arteries:

- Short posterior ciliary arteries.
- Long posterior ciliary arteries.
- Anterior ciliary arteries.

The choroid is supplied by short posterior arteries, reinforced anteriorly by anastomosed recurrent branches from the major arterial circle of iris. Ciliary body and iris are supplied by long posterior ciliary arteries and anterior ciliary arteries via the major arterial circle.

**Venous drainage:** Uveal tract is drained by the following three groups of ciliary veins:

- Short posterior ciliary veins.
- Vortex veins (venae vorticosae).
- Anterior ciliary veins.

**Short posterior ciliary veins** receive blood only from the sclera. **Vortex veins** (four in number) receive blood from the uveal tract with the exception of the outer part of ciliary muscle. These open into ophthalmic veins. **Anterior ciliary veins** receive blood from the outer part of ciliary muscle.

The high vascularity of the uveal tract makes it vulnerable for its frequent involvement in various infections as well as systemic vascular and immune diseases.

## Inflammation (Uveitis) (OP6.1, 6.2, 6.3, 6.8)

The inflammation of the uveal tract is generally not confined to a single part of the uvea and tends to involve uvea as a whole. The inflammation of iris (**iritis**) is almost always associated with

some amount of inflammation of the ciliary body (**cyclitis**) and vice versa.

## Classification

Uveitis may be classified anatomically, clinically, etiologically, and pathologically as follows:

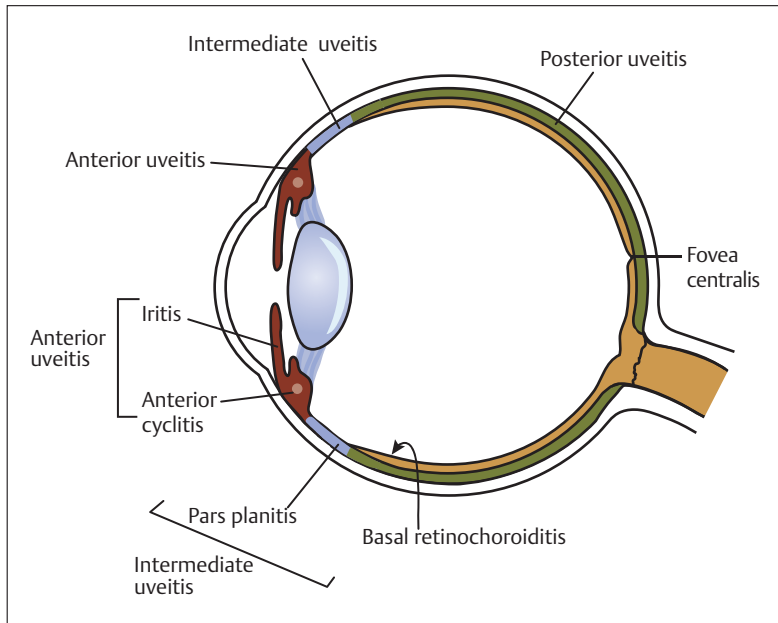
- Anatomical classification (**Fig. 9.7**):
  - ◇ Anterior uveitis.
  - ◇ Intermediate uveitis.
  - ◇ Posterior uveitis.
  - ◇ Panuveitis.
- Clinical classification:
  - ◇ Acute uveitis.
  - ◇ Chronic uveitis.
  - ◇ Recurrent uveitis.
- Etiological classification:
  - ◇ Infective uveitis.
  - ◇ Secondary to systemic diseases.
  - ◇ Neoplastic uveitis.
  - ◇ Traumatic uveitis.
  - ◇ Idiopathic uveitis.
- Pathological classification:
  - ◇ Granulomatous.
  - ◇ Nongranulomatous.

The “International Uveitis study group” has recommended to follow anatomical classification.

## Anatomical Classification of Uveitis

In standardization of uveitis nomenclature (SUN), based on the anatomical site of involvement, uveitis can be:

- Anterior uveitis: It is the inflammation of the anterior uvea (iris and pars plicata of ciliary body). It is further subdivided into–
  - ◇ **Iritis:** Inflammation predominantly involves iris.



**Fig. 9.7** Anatomical classification of uveitis.

- ◇ **Anterior cyclitis:** Inflammation predominantly involves the anterior part of ciliary body (pars plicata).
- ◇ **Iridocyclitis:** Both iris and pars plicata of the ciliary body are equally involved in this condition.
- Intermediate uveitis is subdivided into:
  - ◇ **Pars planitis:** There is predominant involvement of pars plana (the posterior part of ciliary body).
  - ◇ **Basal retinochoroiditis:** There is predominant involvement of the extreme periphery of retina.
- Posterior uveitis: It is the inflammation of the uveal tract posterior to vitreous base. It can be subdivided into:
  - ◇ **Choroiditis:** It is the primary involvement of choroid which may be focal, multifocal, or diffuse.
  - ◇ **Chorioretinitis:** Choroiditis associated with retinitis is known as chorioretinitis.
  - ◇ **Retinochoroiditis:** Here, retina is primarily involved with associated choroidal involvement.
- Panuveitis: It is the inflammation involving the entire uveal tract.

### Clinical Classification of Uveitis

Uveitis is classified according to the mode of onset and duration:

- Acute: It is sudden in onset and symptomatic too. It persists for  $\leq 6$  weeks.
- Chronic: It has insidious onset and asymptomatic. It persists for months/years, or if inflammation recurs in less than 3 months after cessation of therapy.
- Recurrent: When there are repeated episodes of uveitis with period of inactivity (without treatment) between the episodes lasting at least 3 months, it is called recurrent uveitis.

### Etiological Classification of Uveitis

- Infective uveitis: It may be due to:
  - ◇ **Bacterial infections**, for example, tuberculosis, leprosy, gonorrhoea, and brucellosis.
  - ◇ **Spirochaetal infections**, for example, syphilis, leptospirosis, and Lyme disease.

- ◇ *Viral infections*, for example, herpes simplex, herpes zoster, cytomegalovirus (CMV), and acquired immune deficiency syndrome (AIDS).
- ◇ *Fungal infections*, for example, presumed ocular histoplasmosis syndrome (POHS), candidiasis, and cryptococcosis.
- ◇ *Parasitic infections*, for example, toxoplasmosis, toxocariasis, and onchocerciasis.
- Secondary to systemic diseases: Uveitis is found in association with the following diseases:
  - ◇ *Autoimmune disorders*
    - Ankylosing spondylitis.
    - Reiter's disease (or syndrome).
    - Psoriatic arthritis.
    - Juvenile chronic arthritis (JCA).
    - Behcet's syndrome.
    - Rheumatoid arthritis.
    - Systemic lupus erythematosus (SLE).
    - Polyarteritis nodosa.
    - Vogt–Koyanagi–Harada (VKH) syndrome.
  - ◇ *Sarcoidosis*.
  - ◇ *Metabolic disorder*: Diabetes mellitus.
  - ◇ *Gastrointestinal disorders*
    - Whipple's disease.
    - Ulcerative colitis.
    - Crohn disease.
- Neoplastic uveitis: May be associated with
  - ◇ Acute leukemia.
  - ◇ Iris melanoma.
  - ◇ Reticulum cell sarcoma of brain.
  - ◇ Large cell lymphoma.
  - ◇ Histiocytic cell sarcoma.

All these can present features of uveitis and are termed “**masquerade syndromes**.”

- Traumatic—trauma to the eye may be:
  - ◇ Blunt trauma: It may cause uveitis due to mechanical or irritative effect to intraocular blood.
  - ◇ Penetrating injury.
  - ◇ Surgical trauma.
- Idiopathic (uveitis of unknown etiology):
  - ◇ Pars planitis.
  - ◇ Sympathetic ophthalmitis.
  - ◇ Glaucomatocyclitic crisis (Posner–Schlossman syndrome).
  - ◇ Uveitis–glaucoma–hyphema (UGH) syndrome.
  - ◇ Geographical choroidopathy.
- Miscellaneous:
  - ◇ Lens-induced uveitis: It may be phacolytic or phacoanaphylactic.
  - ◇ Fuch's heterochromic iridocyclitis.
  - ◇ Uveitis associated with ocular ischemia: Ischemia alters permeability of vessels, leading to leakage of cells and proteins which, in turn, result in uveitis.

### Pathological Classification of Uveitis

Pathologically, uveitis can be of two types: non-granulomatous and granulomatous (**Table 9.3**).

**Nongranulomatous uveitis:** In this type, the reaction is exudative (or allergic). Exudation of protein-rich fluid results in *aqueous flare*. Outpouring of lymphocytes and polymorphs which adhere to corneal endothelium results in *fine keratic precipitates (KPs)*. It tends to be of *acute onset* and *short duration*.

**Granulomatous uveitis:** It is usually due to invasion of eye by living organisms, but it can also be of immunological etiology. So, hypersensitivity reaction is common in granulomatous uveitis and exudative type of reaction is not encountered. This type of inflammation tends to be of *insidious onset* and *chronic course* with *minimal aqueous flare*. It is common in tuberculosis, leprosy, sarcoidosis, syphilis, etc. Granulomatous uveitis is characterized by dense nodular infiltration of the uveal tissue (**Flowchart 9.1**).

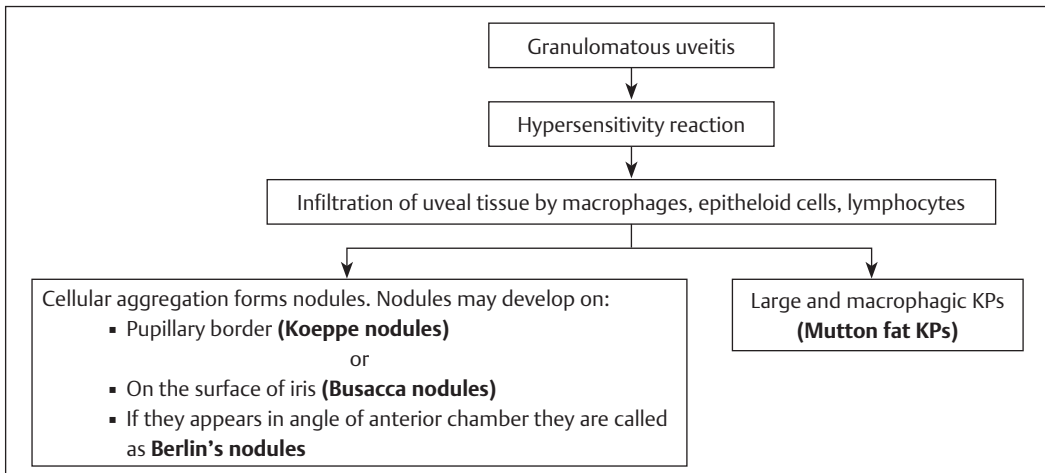
### Investigations

The investigations are ordered after assessing the type of uveitis suspected on clinical examination. If there is single attack of mild, unilateral, acute anterior uveitis without specific features of underlying disease, investigations are not necessary. Indications for investigations

**Table 9.3** Differences between nongranulomatous uveitis and granulomatous uveitis

	Nongranulomatous uveitis	Granulomatous uveitis
<b>Onset</b>	Acute	Insidious
<b>Course</b>	Short	Long
<b>Symptoms</b>		
• Pain	Marked	Minimal
• Photophobia	Marked	Slight
<b>Signs</b>		
• Ciliary congestion	Marked	Mild
• KPs	Fine and lymphocytic	“Large mutton fat” and macrophagic
• Aqueous flare	Marked	Mild
• Iris nodules	Absent	Usually present
• Posterior synechiae	Thin	Thick and broad based

Abbreviation: KP, keratic precipitates.



**Flowchart 9.1** Development of signs in granulomatous uveitis.

are recurrent uveitis, bilateral uveitis, and posterior uveitis. **Table 9.4** lists the investigations performed for uveitis along with the rationale behind those investigations.

### Anterior Uveitis (Iridocyclitis) (OP6.1, 6.2, 6.3, 6.8) (OP6.6)

Clinically, anterior uveitis (iridocyclitis) may present in two forms: acute and chronic, as explained in **Table 9.5**.

## Clinical Features

### Symptoms

The main symptoms of acute anterior uveitis are pain, photophobia, blurred vision, redness, and reflex lacrimation through fifth nerve stimulation supplying iris. Pain is of sudden onset, worse at night, and radiates along distribution of 1st (ophthalmic) division of 5th nerve to forehead, scalp, and cheek. Causes of blurring of vision are depicted in **Fig. 9.8**.



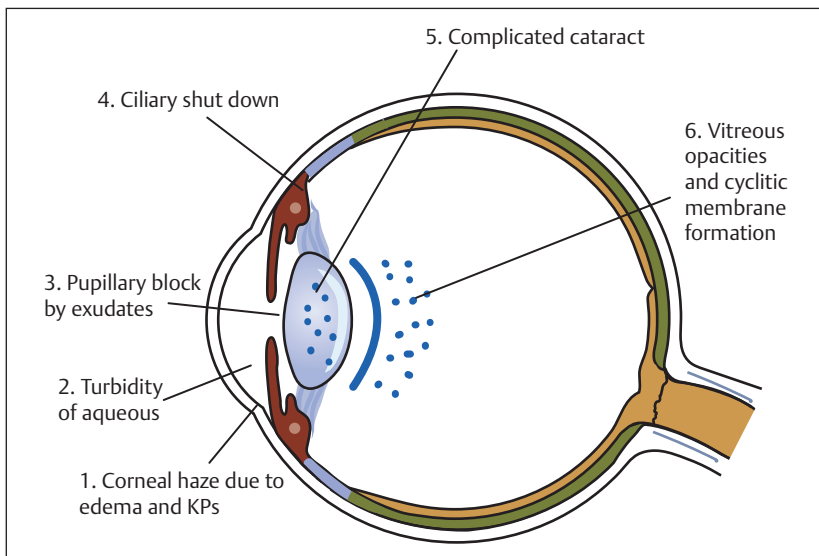
**Table 9.4** Rationale for various investigations

Investigations	Rationale
<ul style="list-style-type: none"> <li>• <b>Hematological</b> <ul style="list-style-type: none"> <li>◇ <b>TLC</b> (Total leucocyte count)</li> <li>◇ <b>DLC</b> (Differential leucocyte count)</li> <li>◇ <b>ESR</b> (Erythrocyte Sedimentation Rate)</li> <li>◇ <b>Blood sugar</b></li> </ul> </li> </ul>	<p><b>TLC and DLC</b> give information about inflammatory response.</p> <p><b>ESR</b> provides information regarding any chronic inflammatory condition.</p> <p><b>Blood sugar</b> is done to rule out diabetes mellitus.</p>
<ul style="list-style-type: none"> <li>• <b>Serological Tests</b> <ul style="list-style-type: none"> <li>◇ <b>VDRL</b> (Venereal Disease Research Laboratory)</li> <li>◇ <b>RPR</b> (Rapid Plasma Reagin)</li> <li>◇ <b>FTA–ABS test</b>: It is highly sensitive and specific (Fluorescent Treponemal antibody absorption test).</li> <li>◇ <b>Sabin–Feldman dye test</b>: It utilizes live organisms.</li> <li>◇ <b>Immunofluorescent–antibody test</b>: It utilizes dead organisms.</li> <li>◇ <b>ELISA</b> (Enzyme Linked Immunosorbent Assay)</li> </ul> </li> </ul>	<p>These tests are done to rule out syphilis.</p> <p>These tests are done for toxoplasmosis.</p>
<ul style="list-style-type: none"> <li>• <b>Enzyme Assay</b> <ul style="list-style-type: none"> <li>◇ <b>Serum ACE</b> (Serum Angiotensin converting enzyme)</li> <li>◇ <b>Serum lysozyme</b> – less specific than ACE</li> </ul> </li> </ul>	<p>These tests are done to rule out <b>sarcoidosis</b>.</p> <p>It is done for uveitis of immunological origin.</p>
<ul style="list-style-type: none"> <li>• <b>HLA [Human Leucocyte Antigen] Tissue Typing</b> HLA type (antigen) <ul style="list-style-type: none"> <li>◇ <b>HLA – B27</b></li> <li>◇ <b>HLA – B51</b></li> <li>◇ <b>HLA – A29</b></li> <li>◇ <b>HLA – B7, HLA – DR2</b></li> </ul> </li> </ul>	<p>Associated disease</p> <ul style="list-style-type: none"> <li>• Ankylosing spondylitis and Reiter's syndrome.</li> <li>• Behcet syndrome.</li> <li>• Birdshot chorioretinopathy.</li> <li>• POHS (Presumed Ocular Histoplasmosis Syndrome).</li> </ul>
<ul style="list-style-type: none"> <li>• <b>Radiological</b> <ul style="list-style-type: none"> <li>◇ X-Ray chest</li> <li>◇ X-Ray sacro-iliac joint</li> </ul> </li> </ul>	<ul style="list-style-type: none"> <li>• It is done to exclude tuberculosis and sarcoidosis.</li> <li>• It is done to exclude ankylosing spondylitis (It should be done in presence of low back pain and uveitis).</li> </ul>
<ul style="list-style-type: none"> <li>• <b>Imaging</b> <ul style="list-style-type: none"> <li>◇ <b>CT and MRI</b> of brain and thorax</li> <li>◇ <b>OCT</b> (optical coherence tomography)</li> <li>◇ <b>Angiography</b></li> </ul> </li> </ul> <p>Fluorescein angiography (FA)</p> <p>Indocyanine green (ICG) angiography</p>	<p>For sarcoidosis and for accompanying cysticercus infection in brain.</p> <p>To detect cystoid macular edema.</p> <p>Fluorescein dye leak out of choroidal vessels resulting in choroidal flush. So, deep lesions will be hidden by this choroidal flush. Thus, <b>FA is less appropriate in choroiditis</b>.</p> <p>ICG dye does not readily leak out of choroidal vessels. Hence, choroidal vessels are better visualized through retinal pigment epithelium. So, <b>ICG angiography is better suited for choroidal diseases</b>. ICG is able to detect nonperfusion of choriocapillaris and provide information about inflammation affecting stroma of choroid.</p>
<ul style="list-style-type: none"> <li>• <b>Skin Test</b> <ul style="list-style-type: none"> <li>◇ <b>Mantoux test</b> (Tuberculin test)</li> <li>◇ <b>Kveim test</b></li> </ul> </li> </ul>	<p>For tubercular uveitis.</p> <p>For sarcoidosis.</p>
<ul style="list-style-type: none"> <li>• <b>Biopsy</b> <ul style="list-style-type: none"> <li>◇ <b>Aqueous samples</b></li> <li>◇ <b>Vitreous biopsy</b></li> <li>◇ <b>Lungs and lymph nodes biopsy</b></li> </ul> </li> </ul>	<p>For polymerase chain reaction (<b>PCR</b>).</p> <p>For culture and PCR.</p> <p>For sarcoidosis.</p>

Abbreviations: ACE, angiotensin-converting enzyme; ANA, antinuclear antibody; DLC, differential leucocyte count; ELISA, enzyme-linked immunosorbent assay; ESR, erythrocyte sedimentation rate; FA, fluorescein angiography; FTA-ABS test, fluorescent treponemal antibody absorption test; HLA, human leucocyte antigen; ICG, indocyanine green; JIA, juvenile idiopathic arthritis; OCT, optical coherence tomography; PCR, polymerase chain reaction; POHS, presumed ocular histoplasmosis syndrome; RPR, rapid plasma reagin; TLC, total leucocyte count; VDRL, venereal disease research laboratory; USG, ultrasonography.

**Table 9.5** Differentiating features of acute and chronic anterior uveitis

Features	Acute anterior uveitis	Chronic anterior uveitis
Occurrence	More common	Less common
Onset	Sudden	Insidious
Duration	3 months or less	Persistent inflammation lasting longer than 3 months
Symptoms	Severe So, patient seeks medical attention	Asymptomatic or minimal symptoms So, diagnosed during routine examination of eye
Laterality	Usually unilateral	Simultaneous bilateral involvement is more common
Course and prognosis	With appropriate therapy completely resolve within 5–6 weeks with an excellent visual prognosis	Remissions and exacerbations of inflammatory activity are common. Prognosis is guarded.
Complications	Are related to delayed or inadequate management	Complications such as cataract and glaucoma are common.

**Fig. 9.8** Causes of blurring of vision in acute anterior uveitis.

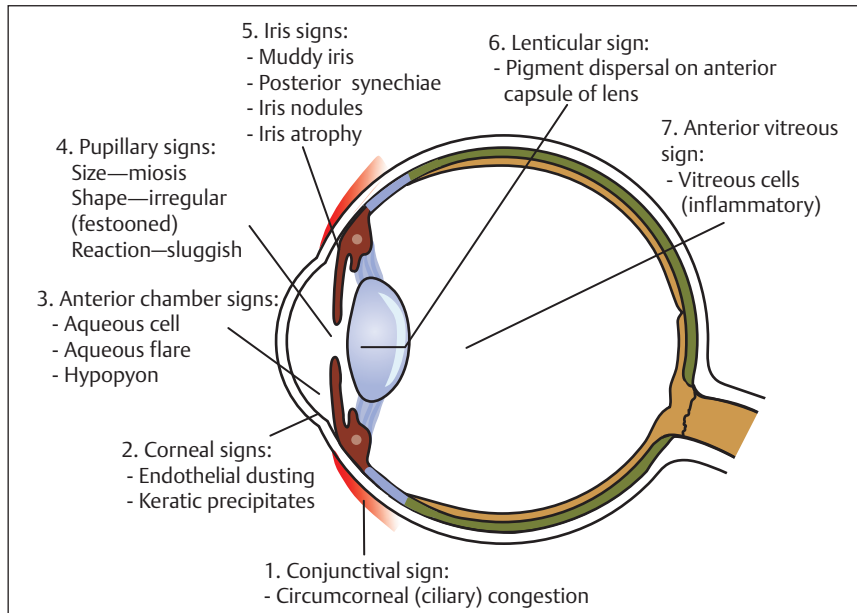
## Signs

Anterior uveitis is characterized by signs, as depicted in **Fig. 9.9**.

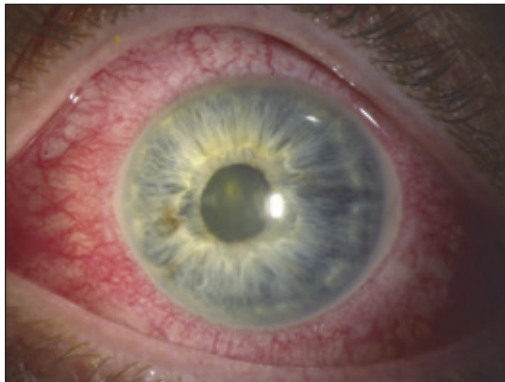
- 1. Circumcorneal (ciliary) congestion:** It is deep and has a violaceous hue (**Fig. 9.10**).
- 2. Corneal signs:**
  - **Endothelial dusting:** It is the deposition of small inflammatory cells on corneal

endothelium in the early stages of uveitis. It gives rise to a dirty appearance.

- **KPs:** These are the clusters of inflammatory cells on corneal endothelium. These appear only after a few days. They are seldom present in simple iritis but are characteristics of cyclitis and iridocyclitis (**Fig. 9.11**).



**Fig. 9.9** Signs in anterior uveitis.



**Fig. 9.10** Anterior uveitis with circumcorneal (ciliary) congestion. Source: Anisocoria. In: Biousse V, Newman N, ed. Neuro-Ophthalmology Illustrated. 3rd Edition. Thieme; 2019.

### Keratic precipitates (KPs)

**Distribution:** KPs are distributed commonly in mid and inferior zones of cornea. Large KPs found in granulomatous uveitis are sometimes distributed over a triangular area, with the apex pointing up, on the inferior part of cornea (Arlt triangle). This is due to the effect of gravity and normal convection flow of aqueous.

**Size:** Small and medium KPs are found in nongranulomatous uveitis and are white and round. Large KPs are usually mutton fat greasy and typically occur in granulomatous uveitis.

**Old KPs:** In nongranulomatous uveitis, KPs shrink, fade, and become pigmented. Old mutton fat KPs take on a “ground glass” appearance (hyalinized).

**KPs are composed of** epithelioid cells, lymphocytes, and polymorphs.

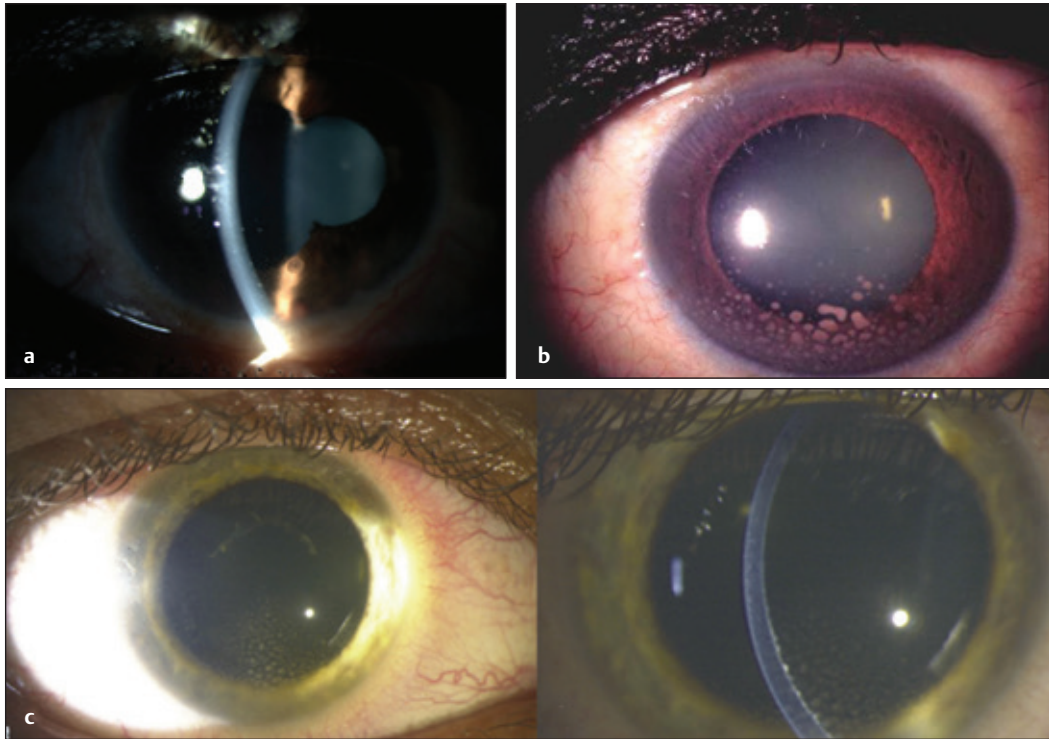
### 3. Anterior chamber signs:

- **Aqueous cells:** Presence of circulating cells is a strong indication of an active inflammation of uvea.
- **Aqueous flare:** It is due to leakage of proteins into aqueous and not necessarily a sign of active uveitis (**Fig. 9.12a**).
- **Hypopyon (OP6.4):** It is a feature of intense inflammation where poured polymorphs settle down at the bottom of anterior chamber to form hypopyon with a horizontal level (**Fig. 9.12b**).

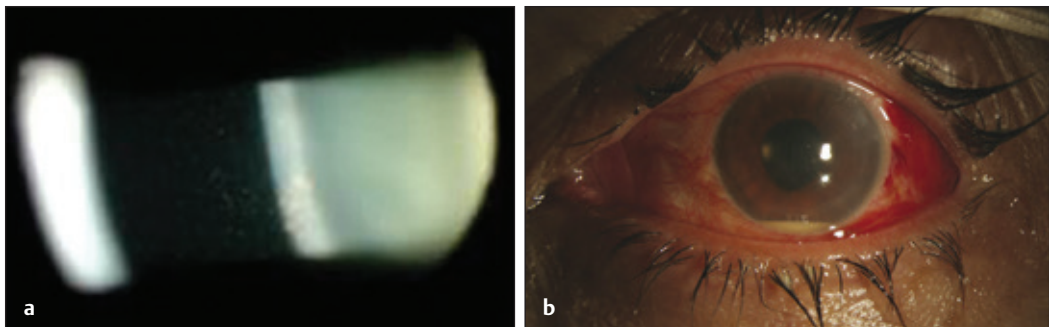
**Grading of aqueous flare and cells** is performed with 2 mm long and 1 mm wide slit beam of slit lamp biomicroscope. Cells are graded by counting cells per field, while aqueous flare is graded by degree of obscuration of iris details (**Table 9.6**).

### 4. Four iris signs:

- **Iris pattern** becomes blurred and indistinct as exudation in iris stroma



**Fig. 9.11** (a) Keratic precipitates. (b) Mutton fat keratic precipitates. (c) Keratic precipitates in anterior uveitis. Source: Ocular Examination. In Biousse V, Newman N, ed. Neuro-Ophthalmology Illustrated. 3rd Edition. Thieme; 2019.



**Fig. 9.12** (a) Aqueous flare and cells. (b) Hypopyon. Source: History In: Singh K, Smiddy W, Lee A, ed. Ophthalmology Review: A Case-Study Approach. 2nd Edition. Thieme; 2018.

causes filling of crypts on the anterior surface of iris (**muddy iris**).

- **Iris nodules:** These are of two types: **Koeppé's nodules**, found at pupillary margin, and **Busacca nodules**, found on anterior surface of iris. *These nodules*

*typically occur in granulomatous uveitis.*

- **Posterior synechiae:** These are the adhesions between anterior lens surface and posterior surface of iris. Posterior synechiae show predilection

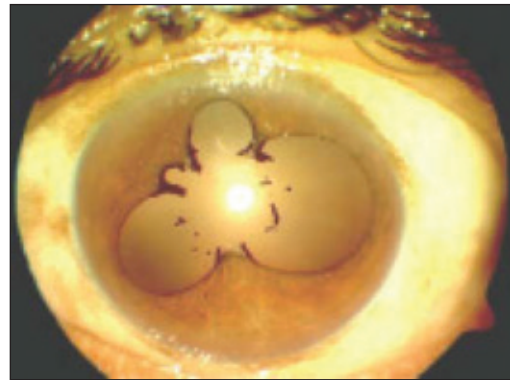
**Table 9.6** Grading of aqueous cells and flare

(a) Grading of aqueous cells		(b) Grading of aqueous flare	
Grade	Cells per field	Grade	Aqueous flare
0	0	0	Absent
+	5–10	+	Faint, barely detectable
++	10–20	++	Moderate (iris details clear)
+++	20–50	+++	Moderate (iris details hazy)
++++	>50	++++	Intense (fibrinous aqueous)

for lower part of pupil in early stages due to the gravitation of exudates. These must not be allowed to become organized. These may be segmental (adhesions at some points) or annular, that is, ring synechiae (extending for 360 degrees). The condition is called **seclusio pupillae**.

- **Iris atrophy:** It is an important feature of Fuchs heterochromic iridocyclitis and uveitis due to herpes virus.
5. **Pupillary signs:**
- **Size—miosis:** Due to spasm of sphincter pupillae.
  - **Shape—irregular shape:** When pupil with segmental posterior synechiae is dilated with mydriatic (atropine and homatropine), intervening portion of pupillary margin (between posterior synechiae) dilate and pupil assumes a festooned appearance (**festooned pupil, Fig. 9.13**).
  - **Reaction—sluggish** pupillary reaction (due to edema of iris).

If exudation from iris and ciliary body is profuse, it may cover the surface of iris as well as the pupillary area. This type of uveitis is called *plastic iridocyclitis*. Exudates upon iris surface may become organized and contract, resulting in eversion of pupillary margin (*ectropion pupillae*). Exudates may block the pupil and get organized. The condition is called *occlusio pupillae*.



**Fig. 9.13** Festooned pupil. Source: Antiinflammatories. In: Agarwal A, Jacob S, ed. Color Atlas of Ophthalmology. The Quick-Reference Manual for Diagnosis and Treatment. 2nd Edition. Thieme; 2009.

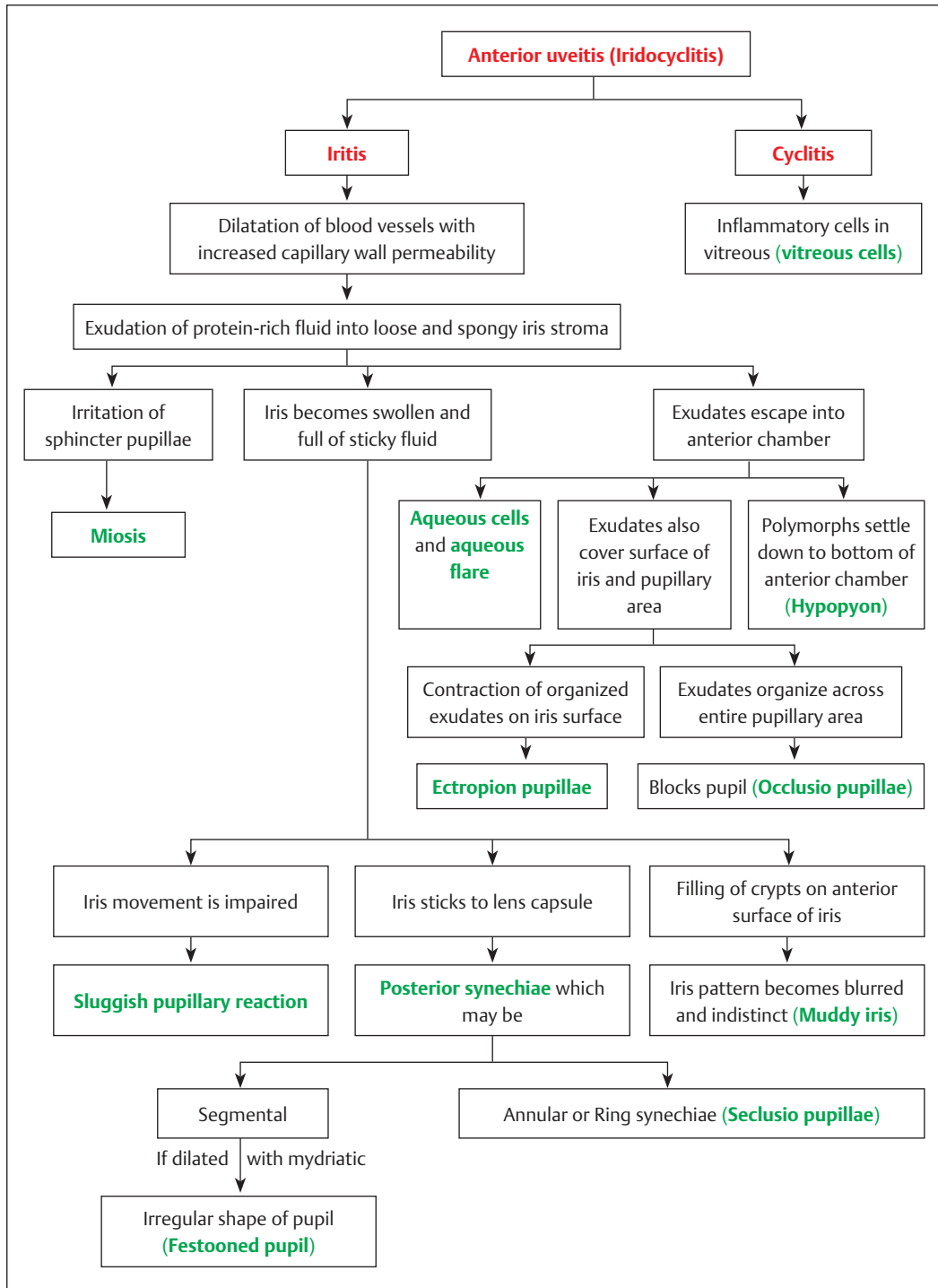
6. **Lenticular sign:** Pigment dispersal on anterior capsule of lens.
7. **Anterior vitreous sign:** *Vitreous cells* (inflammatory cells in anterior vitreous).

In iritis, aqueous cells are more than vitreous cells.

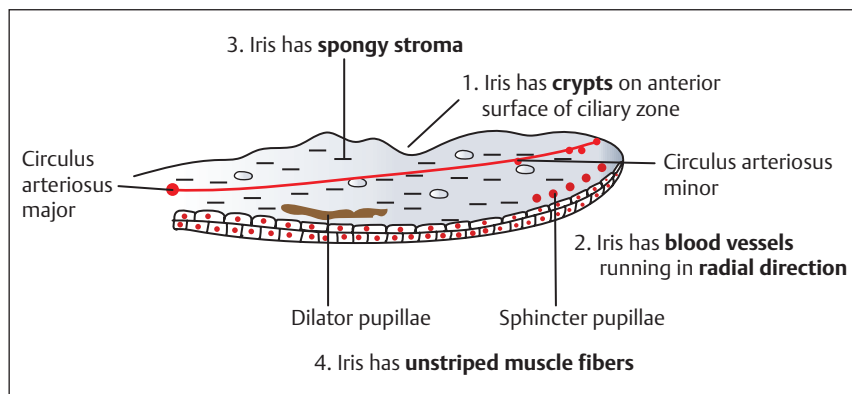
In iridocyclitis, cells are equally distributed in aqueous and vitreous humor.

In cyclitis, exudates in vitreous are more. When they organize, they form *cyclitic membrane* behind the lens.

To understand the development of signs in anterior uveitis, it is necessary to remember the anatomy and pathological changes occurring in the iris (**Fig. 9.14** and **Flowchart 9.2**).



Flowchart 9.2 Pathological changes in iris.



**Fig. 9.14** Anatomy of iris.

### Anatomy of Iris

1. Iris has **crypts** on the anterior surface of ciliary zone.
2. Iris has **blood vessels** running in the radial direction.
3. Iris has **spongy stroma** consisting of loosely arranged collagenous network.
4. Iris has **unstriated muscle fibers**.

### Investigations

- Hematological investigations (total leucocyte count [TLC], differential leucocyte count [DLC], erythrocyte sedimentation rate [ESR], blood sugar).
- Serological test (antinuclear antibody [ANA], rheumatoid factor, human leucocyte antigen [HLA] typing, venereal disease research laboratory [VDRL], fluorescent treponemal antibody absorption test [FTA-ABS], enzyme-linked immunosorbent assay [ELISA], etc.).
- Radiological investigations (X-ray chest and sacroiliac joints, CT scan).
- Skin test (Mantoux test and Kveim test).
- Urine examination to rule out urethritis.
- Anterior chamber paracentesis for polymerase chain reaction (PCR) to diagnose organisms and cellular analysis.

### Differential Diagnosis (OP3.1)

Acute iridocyclitis must be differentiated from acute conjunctivitis and acute angle closure

glaucoma (**Table 9.7**). *Dilatation of pupil is urgently required in acute anterior uveitis (iridocyclitis), but it may worsen acute angle closure glaucoma, so it is a must to differentiate between the two.*

### Treatment

It includes general treatment of uveitis with cycloplegics and mydriatics, corticosteroids and immunosuppressives; specific treatment of underlying cause; and treatment of sequelae and complications.

### General Treatment (OP6.9)

#### Cycloplegics and Mydriatics

Short-acting preparations are Tropicamide 0.5% or 1% drops and Cyclopentolate 1% drops, while long-acting preparations are Homatropine 2% drops and Atropine 1% drops or ointment (most powerful cycloplegic).

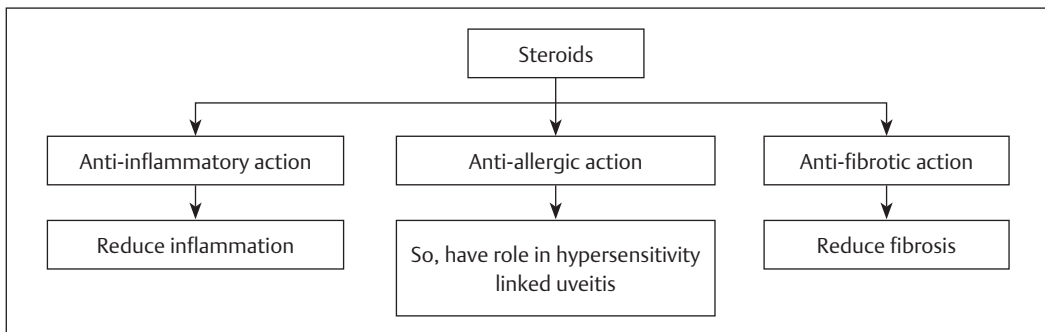
#### Mode of Action

These relieve the spasms of ciliary muscle and sphincter pupillae so, give comfort and rest to the eye. These prevent formation of posterior synechiae. It is best achieved by short-acting cycloplegics which keep the pupil mobile. Pupil should not be kept constantly dilated in chronic anterior uveitis, as posterior synechiae can still form in dilated position. These break down recently formed posterior synechiae. Once synechiae have formed, topical Atropine 1% drop or ointment is used.

**Table 9.7** Differentiating features of acute conjunctivitis, acute anterior uveitis and acute angle closure glaucoma (OP6.1)

	Acute conjunctivitis	Acute anterior uveitis	Acute angle closure glaucoma
<b>Symptoms</b>			
• Discharge	Mucopurulent	Watery	Watery
• Colored halos	May be present	–	+
• Vision	Normal	Slightly impaired	Markedly impaired
• Pain	±	Moderate	Severe
<b>Signs</b>			
• Congestion (injection)	Superficial	Deep ciliary	Deep ciliary
• Cornea	Normal	KPs on endothelium	Epithelial edema
• Aqueous	Clear	Flare ++	Flare ±
• Pupil			
◊ Size	Normal	Small	Dilated
◊ Shape	Normal	Irregular	Vertical oval
◊ Reaction	Brisk	Sluggish	Non reacting
• IOP	Normal	Often normal	Markedly raised
• Tenderness	–	+	+

Note: (+) denotes presence and (–) denotes absence. Abbreviations: KP, keratic precipitates; IOP, intra ocular pressure.



**Flowchart 9.3** Mode of action of corticosteroids in the treatment of anterior uveitis.

In eyes that do not respond to mydriatic drops, a *subconjunctival (s/c) injection* of mydricaine 0.3 mL (a mixture of adrenaline + atropine + procaine) may be effective. *Subconjunctival mydricaine induces tachycardia and hypertension, so should be used cautiously in patients with cardiovascular disease.* To breakdown persistent posterior synechiae “*tissue plasminogen activator*” is injected into anterior chamber. It dissolves fibrinous exudates. When the pupil is well dilated,

frequency of instillation is gradually reduced and then discontinued.

**Corticosteroids**

These are the mainstays in the treatment of uveitis. Potent steroid preparations include betamethasone, dexamethasone and prednisolone, while weak steroid preparations include fluorometholone and loteprednol. Mode of action of corticosteroids in the treatment of anterior uveitis is described in **Flowchart 9.3**.



### Routes of Administration

**Topical steroids:** These are given in the form of eye drops and ointment. Frequency of instillation depends on the severity of inflammation. Initially, potent steroids are given. Weaker steroids are used as the inflammation subsides. Weaker preparations are reserved for mild uveitis in patients who are steroid responders.

*Complications of topical steroids* include elevation of intraocular pressure (IOP), cataract, corneal melting due to inhibition of collagen synthesis, and secondary infection with bacteria and fungi.

**Periocular injections:** Subconjunctival injections or anterior subtenon injections are given mainly in severe cases of anterior uveitis. Short-acting (1 day) preparations include betamethasone and dexamethasone. Long-acting (several weeks) preparations include triamcinolone acetonide and methylprednisolone acetate.

**Systemic administration:** It is given orally and includes prednisolone which is given in initial dose of 1 to 2 mg/kg body weight/day (60–80 mg/day) as a single morning dose after breakfast. The dose is gradually tapered over several weeks to avoid reactivation. If steroids are given for <2 weeks, there is no need to reduce the dose gradually. There are certain side effects from the use of systemic therapy. Short-term therapy causes dyspepsia and peptic ulceration, and also mental changes. Prednisolone can cause mental problems, including psychosis, mania and clinical depression. Severe psychiatric illness was uncommon with dose less than 40 mg/day of prednisolone, but increased doses above 80 mg/day of prednisolone strongly supporting that these symptoms are dose-dependent. Long-term therapy causes cataract (posterior sub capsular), worsening of diabetes, cushingoid state, osteoporosis, electrolyte imbalance, and reactivation of infections such as TB. *Presence of a flare in absence of cells is not an indication for systemic steroid therapy.*

### Immunosuppressive (Cytotoxic Agents)

These are given to patients who do not respond to systemic steroids. Drugs used for immunosuppression are azathioprine, cyclophosphamide, chlorambucil, cyclosporin and methotrexate. All of these drugs are potentially toxic. Complications of immunosuppression are bone marrow depression, hepatotoxicity, gastro-intestinal ulceration, sterility, alopecia, and nephrotoxicity (with cyclosporin). Monitoring with immunosuppressives is done by complete blood count, liver function tests (because of hepatotoxicity) and renal function tests (because of nephrotoxicity).

### Specific Treatment of Underlying Cause

When exact etiology is identified, the underlying disease needs the specific treatment.

### Treatment of Sequelae and Complications

**Glaucoma (*Hypertensive iridocyclitis*):** In this condition, IOP increases due to inflammation before the synechiae develops (inflammatory glaucoma). It requires the following:

- Control of inflammation by steroids and atropine.
- Lowering of IOP by systemic acetazolamide, 250 mg 4 times a day and 0.5% Timolol maleate eye drops.

Pilocarpine and Latanoprost are contraindicated as uveitis may be exacerbated.

**Secondary glaucoma:** Secondary glaucoma develops after ring synechiae, so the aim of treatment is to restore communication between posterior and anterior chambers which is achieved by:

- Laser iridotomy.
- Surgical iridectomy: It is not done during acute stage of iritis because opening will be filled with exudates, and the aim of operation will not be achieved.

**Complicated cataract:** The lens is removed surgically 2 to 3 months after a quiescent interval of acute iritis.

**Band keratopathy:** It is treated with excimer laser photoablation or phototherapeutic keratectomy (PTK).

**Cystoid macular edema (CME):** Intravitreal triamcinolone is given for it.

## Complications

- **Complicated cataract:** It is characterized by polychromatic luster at the posterior pole of lens. Cataract progresses rapidly in the presence of posterior synechiae.
- **Cyclitic membrane (retrolental membrane):** It is due to organized exudates behind the lens in severe cases of plastic uveitis.
- **Rise of IOP:** In the active stage of iridocyclitis, sticky albuminous aqueous clogs the trabecular meshwork at the angle of anterior chamber. It results in reduced aqueous drainage and rise in IOP (**hypertensive iridocyclitis**). In the later stages, pupillary block due to seclusio pupillae or occlusio pupillae reduces the flow of aqueous from posterior chamber to anterior chamber. It results in iris bombe. The apposition of iris to cornea at periphery forms peripheral anterior synechiae, with subsequent obliteration of angle of anterior chamber. It causes rise in IOP (**secondary glaucoma**).
- **Panuveitis and retinal complications:** In cases of longstanding uveitis, choroid is involved, owing to the continuity and resulting in panuveitis which, in turn, may cause retinal complications such as exudative retinal detachment, cystoid macular edema and neuro retinitis.

In plastic uveitis, exudates and strands of fibrous tissue are formed in vitreous. Contraction of these fibrous strands, formed in vitreous and attached to retina, may result in tractional retinal detachment.

- Band-shaped keratopathy.

- **Phthisis bulbi:** Chronic and recurrent uveitis can lead to degenerative changes in ciliary body with reduced aqueous secretion. It results in **ocular hypotony** (soft eye) with shrinkage of eyeball (Phthisis bulbi).

## Intermediate Uveitis (Pars Planitis)

It is also known as *chronic posterior cyclitis*. It involves pars plana of ciliary body and periphery of choroid. It is an insidious, chronic, and relapsing disease. It particularly affects a child or a young adult. The condition is typically bilateral (80%) but involvement is frequently asymmetrical. Etiology is usually unknown.

## Systemic Associations

### Infections

- Tuberculosis.
- Syphilis.
- Toxocariasis.

## Noninfectious Systemic Diseases

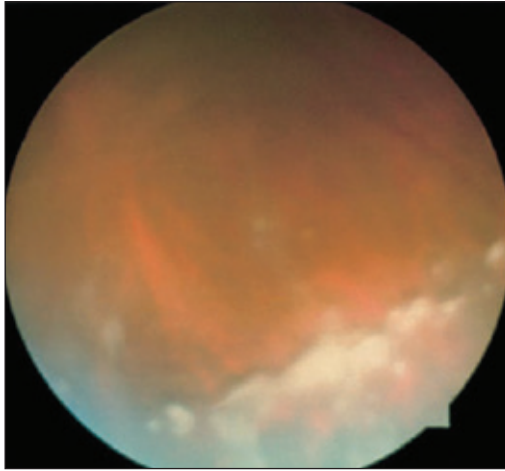
- Multiple sclerosis.
- Sarcoidosis.

## Masquerade Syndromes

- Retinoblastoma.

It presents as floaters in the eye and leads to blurring of vision. Blurred vision is due to opacities in anterior vitreous. It is characterized by the presence of the following clinical signs:

- Cells in anterior vitreous.
- White snowball-like exudates near ora serrata, involving inferior pars plana. Coalescent exudates give the appearance of a “snow bank” (**snow banking, Fig. 9.15**).
- Mild peripheral periphlebitis and perivascular sheathing.
- Absent or minimal anterior uveitis with minimal aqueous flare and occasional KPs.
- Posterior synechiae are absent.



**Fig. 9.15** Snow banking in pars planitis. Source: Intermediate Uveitis. In: Steidl S, Hartnett M, ed. Clinical Pathways in Vitreoretinal Disease. 1st Edition. Thieme; 2003.

## Differential Diagnosis

Pars planitis must be differentiated from chronic conditions which produce vitritis or peripheral retinal changes, mimicking pars planitis, for example:

- Peripheral toxocariasis.
- Syphilis.
- Sarcoidosis.
- Multiple sclerosis.
- Whipple disease (vitritis without snowballs).

## Investigations

Ocular:

- Optical coherence tomography (OCT): To diagnose macular complications.
- Fundus fluoresceine angiography (FFA): To diagnose CME and peripheral retinal vasculitis.

Systemic:

- Chest X-ray and HRCT: For TB and sarcoidosis.
- Treponema pallidum Haem agglutination (TPHA) test: For syphilis.

- IgM and IgG: For toxocara.
- MRI of the brain: For multiple sclerosis.

## Treatment

The main **indication** of treatment is decreased visual acuity due to chronic macular edema. The treatment includes:

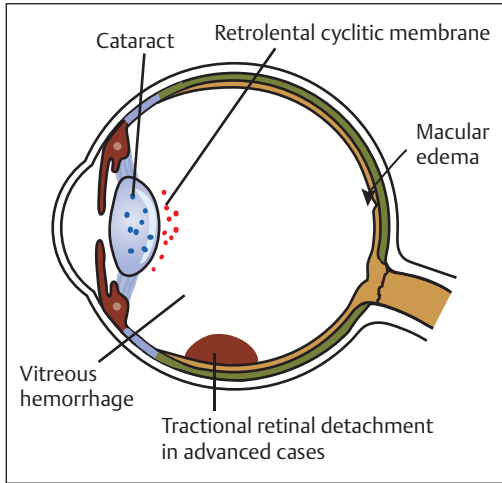
- Posterior subtenon injection of triamcinolone should be given initially. The patient is advised to look inferonasally. Steadily 40 mg/mL of triamcinolone is injected in the superotemporal quadrant of the globe. The needle is advanced along the contour of the globe. The drug is delivered after withdrawing to check for vascular entry.
- In the event of resistance to injections (in unresponsive cases), systemic steroids are given.
- In severe steroid resistant cases, immunosuppressive agents are considered.
- Vitrectomy: It is indicated in case of tractional retinal detachment, nonresolving vitreous hemorrhage, and severe vitreous opacification.

## Complications

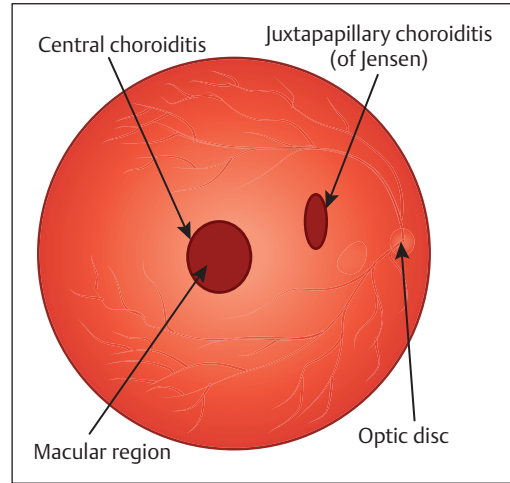
- Macular edema: If it becomes chronic, cystoid changes develop (cystoid macular edema).
- Cataract.
- Retrolental cyclitic membrane.
- In advanced cases, exudate becomes vascularized, resulting in contraction of fibrovascular tissue and leading to tractional retinal detachment and vitreous hemorrhage (**Fig. 9.16**).

## Posterior Uveitis

Posterior uveitis is the inflammation of choroid (posterior uvea). The inflammation of choroid almost always involves retina, because outer layers of retina depend upon choroid for their



**Fig. 9.16** Complications of intermediate uveitis.



**Fig. 9.17** Types of focal choroiditis.

nourishment. According to the site of primary involvement, posterior uveitis can be:

- Chorioretinitis: The primary focus is on choroid.
- Retinochoroiditis: The primary focus is on retina.

### Classification

According to the number and location of areas involved, choroiditis can be focal, multifocal and diffuse.

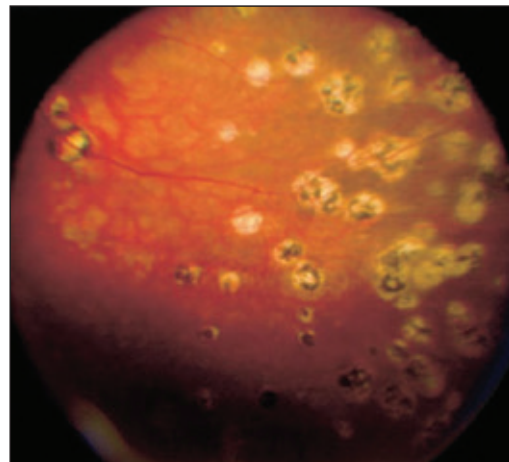
#### Focal Choroiditis

It is characterized by a patch (or patches) of choroiditis localized in a particular area. It may be (**Fig. 9.17**):

- *Central*: If choroiditis involves posterior pole or macular region.
- *Juxtapapillary*: If patch of choroiditis is close to the optic disc.

#### Multifocal Choroiditis

It is the choroiditis with fewer and more discrete foci. When it is confined to anterior (peripheral) part of choroid, it is termed as anterior choroiditis (**Fig. 9.18**).



**Fig. 9.18** Multifocal choroiditis. Source: Signs and Symptoms of Uveitis. In: Steidl S, Hartnett M, ed. Clinical Pathways in Vitreoretinal Disease. 1st Edition. Thieme; 2003.

#### Disseminated or Diffuse Choroiditis

When multiple, small areas of inflammation are scattered all over the fundus behind the equator, it is called disseminated choroiditis. It is syphilitic or tuberculous in origin. The healed lesions appear as atrophic patches.

## Causes

### Infectious causes:

- Bacterial:
  - ◊ Tuberculosis.
  - ◊ Syphilis.
- Viral:
  - ◊ Cytomegalovirus (CMV).
  - ◊ Herpes simplex and zoster.
- Protozoal:
  - ◊ Toxoplasma.
  - ◊ Toxocara.
- Fungal:
  - ◊ Candida.
  - ◊ Aspergillus.

### Noninfectious causes:

- VKH syndrome.
- Sarcoidosis.
- Behcet syndrome.

## Clinical Forms

Clinically, it is similar to iridocyclitis, and may be granulomatous and nongranulomatous choroiditis. Nongranulomatous choroiditis (also known as exudative choroiditis) is characterized by acute leucocytic infiltration and marked exudation. Granulomatous choroiditis is usually associated with direct organismal infection and characterized by aggregation of chronic inflammatory cells (lymphocytes, plasma cells, etc.).

## Clinical Features

### Symptoms

The presenting symptoms vary according to the location of inflammatory lesion. Peripheral lesions present with floaters and minimal visual symptoms, while central lesions cause marked blurring of vision and may not notice the presence of floaters. Various visual symptoms related to central choroiditis are:

- Black spot in front of eye (positive scotoma).
- Retinal irritability leading to subjective sensation of flashes of light (photopsia).

- Inflamed area is slightly raised, causing alterations in the contour of retina. These alterations further lead to:
  - ◊ Distortion of image and apparent change in size of objects (metamorphopsia).
  - ◊ Straight lines appear wavy.
  - ◊ Objects appear small (micropsia) due to separation of rods and cones, and sometimes larger (macropsia) due to crowding of rods and cones.

## Signs

**In active stage:** Inflammatory cells and *vitreous opacities* are present. The patch of choroiditis is seen as a *yellowish area deep to retinal vessels*. Retinal signs include exudates in retina, edema of overlying retina and retinal vasculitis. In this, commonly retinal veins are involved (periphlebitis) with sheathing of vessels.

**In healed stage:** White areas are surrounded by black pigment clumps at the edges, and the affected area becomes more sharply defined, lying deep to retinal vessels (*in retinitis pigmentosa, retinal pigment lies anterior to retinal vessels*) (Table 9.8).

## Treatment

Topical steroids are useful only for anterior uveitis, because therapeutic levels are not reached behind the lens. Treatment protocols include the following:

- Periocular injection: Periocular steroids should be considered as first-line therapy to control inflammation and CME. Posterior subtenon injection of long-acting preparations such as triamcinolone or methylprednisolone is given. *Complications* of posterior subtenon injection are:
  - ◊ Globe penetration.
  - ◊ Elevation of IOP.
  - ◊ Optic nerve injury.
  - ◊ Extraocular muscle (EOM) paresis.
- Intraocular steroids: Triamcinolone injection 4 mg in 0.1 mL is given in treatment

**Table 9.8** Difference between retinitis and choroiditis

	Retinitis	Choroiditis
<b>Appearance</b>	<ul style="list-style-type: none"> <li>• Retinal vessels not seen over the lesions</li> <li>• Bright yellow lesion</li> </ul>	<ul style="list-style-type: none"> <li>• Vessels are seen over the lesion</li> <li>• Dull yellow lesion deep to the retina</li> </ul>
<b>Etiology</b>	<ul style="list-style-type: none"> <li>• Almost always infectious</li> </ul>	<ul style="list-style-type: none"> <li>• Both infectious and noninfectious</li> </ul>
<b>Vitritis</b>	<ul style="list-style-type: none"> <li>• More common</li> </ul>	<ul style="list-style-type: none"> <li>• Not seen unless the overlying retina is involved</li> </ul>
<b>Healing pattern</b>	<ul style="list-style-type: none"> <li>• Thinning/atrophic retina</li> </ul>	<ul style="list-style-type: none"> <li>• Heals with pigmentation</li> </ul>

of uveitis and CME unresponsive to other forms of therapy. It produces fast resolution of CME.

*Complications of intraocular steroids* are:

- ◇ Rise of IOP.
- ◇ Cataract.
- ◇ Endophthalmitis.
- ◇ Retinal detachment.
- Systemic steroids: These are indicated when there is no improvement with periocular steroids or when posterior uveitis is sight threatening. Routes of administration are IV and oral administration. IV methylprednisolone in dose of 1 g/day through infusion bottle is given for 3 days, followed by oral prednisolone given in the dose of 1–2 mg/kg body wt/day and tapered gradually over several weeks.
- Specific treatment of underlying cause.

## Complications

- Complicated cataract owing to impaired nutrition of lens.
- Papillitis.
- Retinal detachment.

## Specific Types of Uveitis

### Bacterial Uveitis

#### Tubercular Uveitis

It is a chronic granulomatous infection caused by mycobacterium tuberculosis. It can cause either a direct infection or a delayed hypersensitivity

reaction in the uveal tissue. Tuberculosis can involve both anterior and posterior uvea.

#### Ocular Manifestations

**Anterior uveitis:** It is usually granulomatous but occasionally it may be nongranulomatous. Granulomatous type may occur in the miliary form (yellowish white nodule surrounded by multiple satellites) or conglomerate form (larger yellowish white tumor).

**Posterior uveitis:** Tuberculous choroiditis is caused by direct infection. It can manifest as:

- Multiple, miliary tubercles in choroid (choroidal tubercles).
- Disseminated choroiditis.
- Large, solitary choroidal granuloma (choroidal tuberculoma).

#### Choroidal tubercles:

- Occur predominantly in the posterior pole.
- Solitary or multiple lesions (multifocal choroiditis).
- Size: 0.3 to 3.0 mm in diameter.
- Color: Appear yellowish, grayish, or whitish.
- May have overlying serous retinal detachment (RD).

#### Choroidal tuberculoma:

- Present as solitary raised lesion.
- Color: Grayish white.
- Size: 2 to 3 DD within distinct margins.
- Overlying exudative RD.
- FA: Choroidal tuberculoma may show early hyperfluorescence and leakage around the margins in later phases.

- USG:
  - ◇ Shows acoustically dense lesions with no choroidal excavation.
  - ◇ Low internal reflectivity and high vascularity.

Other intraocular manifestations in TB include:

- Retinal vascularitis and Eales' disease. It is presumed to be an immunological response to the microbacteria.

Retinal vasculitis from direct infection is rare.

### Diagnosis

Diagnosis is reached with the help of the following investigations:

- Mantoux test.
- Chest X-ray.
- ESR.
- PCR on samples obtained from ocular tissues.
- Histopathology of ocular tissues to demonstrate tubercular bacilli.
- Therapeutic isoniazid test: If there is a dramatic improvement in uveitis to 300 mg/day isoniazid for 3 weeks, the diagnosis of tuberculosis is highly likely.

### Differential Diagnosis

Various entities that mimic tubercular uveitis are:

- Sarcoidosis.
- Syphilitic gummas.
- Toxoplasmosis.
- Toxocariasis.
- Nocardiasis.
- Brucellosis.
- Behcet's syndrome.
- Leprosy.

### Pathology

It consists of:

- Central caseation surrounded by epithelioid cells, giant cells, and lymphocytes.

*Absence of giant cells and caseation, however, does not exclude the diagnosis of TB.*

- In immunocompromised individuals, histopathology reveals mononuclear cells only with no epithelioid cells and giant cells but with abundant acid-fast bacilli.

### Treatment

Usual treatment of anterior uveitis is recommended. Antitubercular treatment (ATT) is also given. This included a 4-drug regimen (isoniazid + rifampicin + ethambutol + pyrazinamide) for 2 months followed by isoniazid + rifampicin for 6 months. Concomitant systemic steroid therapy is also frequently necessary. *Ethambutol may cause optic neuropathy*. So, periodical eye examination is needed.

### Leprotic Uveitis

Leprosy (Hansen's disease) is caused by *Mycobacterium leprae*. It predominantly involves skin, peripheral nerves, and anterior segment of the eye. Two types of leprosy are lepromatous (cutaneous) type and tuberculoid (neural) type (**Table 9.9**).

#### Ocular Manifestations

Involvement of anterior segment of the eye causes uveitis. Involvement of peripheral nerves leads to varied types of symptoms, for example:

- Involvement of facial nerve causes neuroparalytic lagophthalmos, leading to exposure keratopathy.

**Table 9.9** Differentiating features of different types of leprosy

	Lepromatous type	Tuberculoid type
• Cellular immunity	Depressed	Good
• Ocular involvement	It is due to direct invasion of iris by bacilli	It is indirect due to involvement of peripheral nerves resulting in neuroparalytic and neurotrophic keratopathy
• Uveal involvement	More common	Rare

- Involvement of trigeminal nerve causes either loss of corneal sensations, leading to neurotrophic keratopathy or loss of iris sensations. *Hence, eye with chronic uveitis usually tolerates surgery for secondary cataracts.*
- Damage to sympathetic innervation of dilator pupillae causes unopposed action of sphincter pupillae, leading to miosis.

Other ocular features include conjunctivitis, episcleritis, keratitis, uveitis, miosis and iris atrophy. Leprosy involves predominantly anterior uvea. Lepromatous leprosy may result in **granulomatous anterior uveitis**. It is characterized by presence of small, glistening nodules known as **iris pearls**—a *pathognomonic sign*. Iris pearls are composed of dead bacilli within histiocytes which are located at the pupillary margin and resemble a necklace. There is low-grade inflammation associated with formation of synechiae.

### Diagnosis

- It is confirmed by histology of the skin lesions.
- Iris pearls are characteristic.
- Skin test with lepromin: It may be highly positive (**Mitsuda reaction**) in the tuberculoid type.

### Differential Diagnosis

- Tuberculosis.
- Sarcoidosis.
- Syphilis.
- Idiopathic.

### Systemic Associations

These consist of:

- Hypopigmented skin lesions.
- Skin anesthesia.
- Thick and peripheral nerves.
- Deformed hands and feet.
- *Leonine facies*.

### Pathology

- **Tuberculoid form**: It is characterized by an active cell-mediated immune response. So, it is characterized by granuloma formation and lack of bacilli.
- **Lepromatous leprosy**: It comprises:
  - ◇ Macrophages with numerous acid-fast bacilli.
  - ◇ Iris pearls consist of macrophages filled with bacilli.

### Treatment

It includes local treatment of anterior uveitis and also specific treatment for leprosy. **Dapsone** 50 to 100 mg/day for 1 to 2 years is the drug of choice for the treatment of leprosy. Dapsone is a systemic sulphone. Other drugs recommended by WHO are **clofazimine and rifampicin**. They are potent drugs effective against resistant cases.

### Uveitis in Sarcoidosis

It is a systemic disease of unknown etiology characterized by formation of **noncaseating** granuloma in affected tissues. The clinical presentation may vary from single organ involvement to multisystem involvement. Commonly involved tissues are lungs, skin, joints, eyes, central nervous system (CNS), liver and spleen.

### Ocular Manifestations

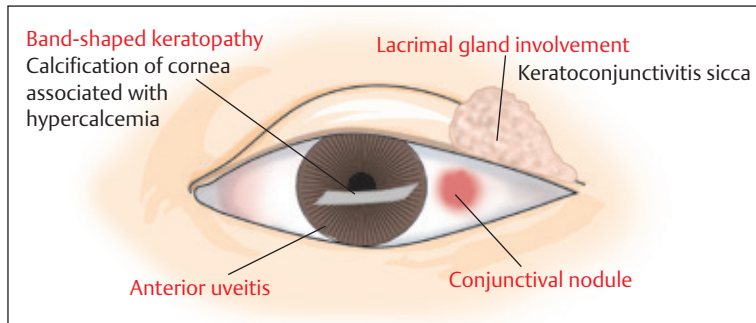
**Uveitis** is the most common ocular manifestation. It may involve the anterior or posterior segment.

**Anterior segment** involvement presents as (**Fig. 9.19**):

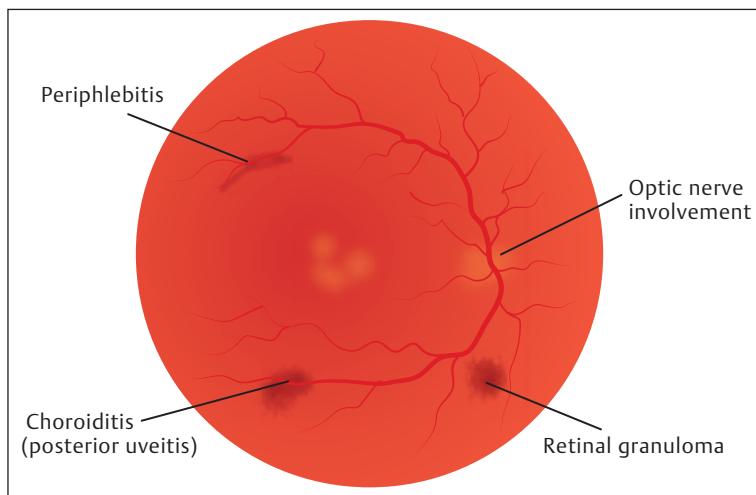
- Anterior uveitis:
  - ◇ Acute iridocyclitis.
  - ◇ Chronic iridocyclitis: It is granulomatous, usually bilateral, and more common than acute form.

Busacca and Koeppe nodules are not uncommon. Nodular deposit in the angle can lead to increased IOP. Patients with chronic pores





**Fig. 9.19** Ocular lesions in sarcoidosis due to anterior segment involvement.



**Fig. 9.20** Ocular lesions in sarcoidosis due to posterior segment involvement.

and multiple exacerbations are at higher risk of secondary glaucoma or cataract.

- Other ocular features:
  - ◇ Conjunctival nodules.
  - ◇ Band-shaped keratopathy.
  - ◇ Keratoconjunctivitis sicca (due to lacrimal gland involvement)

Involvement of both lacrimal and salivary glands constitute **Mikulicz syndrome**.

Band-shaped keratopathy, though associated with sarcoidosis, is rarely a primary event and is more likely to be a complication of chronic uveitis.

**Posterior segment** manifestations are caused by involvement of:

- Choroid: Choroidal involvement may result in *posterior uveitis (chorioretinitis)* and *choroidal or retinal granuloma* (**Fig. 9.20**).

- Periphlebitis and vitritis are the most common manifestations of posterior uveitis in sarcoidosis.
- Blood vessels: Involvement of blood vessels cause peripheral retinal periphlebitis which is characterized by:
  - ◇ Perivenous sheathing.
  - ◇ Peripheral retinal hemorrhages due to increased vascular permeability.
  - ◇ Perivenous exudates known as “**candle wax drippings**.”
  - ◇ A cellular reaction in anterior vitreous may accompany the periphlebitis.

**Uveoparotid fever:** Sarcoidosis may present as **uveoparotid fever (Heerfordt’s syndrome)**. It is bilateral and characterized by simultaneous involvement of uveal tract (causing granulomatous

anterior uveitis), parotid gland (painful swelling of parotid resembling mumps, causing fever and malaise and cranial nerves (causing facial palsy and ocular motor nerves palsy leading to diplopia). It affects young individuals between 10 and 30 years of age.

### Investigations

- Serum angiotensin-converting enzyme (ACE) is raised.
- Estimation of serum lysozyme.
- X-ray chest may show bilateral involvement of hilar lymph nodes in lungs.
- Skin test: **Kveim test** (injection of sarcoid tissue suspension into skin of sarcoidosis patient) is positive. *Mantoux test is negative in most patients.* Patient's sarcoidosis often fails to react to intradermal injection of tuberculin.

A strongly positive reaction to tuberculin makes the diagnosis of sarcoidosis highly unlikely.

- Biopsy of lungs, conjunctival nodules, lacrimal glands, lymph nodes or skin lesions.
- HRCT of the chest to look for lymph nodes.
  - ◇ Gallium scanning: It is based on the tendency of gallium to accumulate at sites of inflammation. It is especially useful in normal chest radiographs but laboratory/clinical findings consistent with sarcoidosis. Bilateral hilar uptake combined with increased uptake in parotids and orbits is highly characteristic of sarcoid. Gallium scanning combined with serum ACE provides increased sensitivity and specificity.

### Treatment

Treatment includes administration of steroids, which may be topical, periocular, and systemic. Immunosuppressives (methotrexate or cyclosporin) are rarely required.

## Viral Uveitis

### Herpetic Uveitis

Herpes viruses are:

1. **Herpes simplex virus (HSV)**, which has 2 subtypes:
  - HSV-1
  - HSV-2

*HSV-1* affects the area supplied by trigeminal or sacral ganglia. *HSV-2* mostly affects genitals. HSV causes *Herpes simplex* which affects human being early in life.

2. **Varicella zoster virus (VZV)**: It causes herpes zoster and commonly involves the ophthalmic (1st) division of trigeminal nerve (*Herpes zoster ophthalmicus [HZO]*).

### Ocular Manifestations

Herpes viruses cause granulomatous chronic anterior uveitis, acute retinal necrosis (**ARN**) and progressive outer retinal necrosis (**PORN**).

#### Granulomatous Chronic Anterior Uveitis

**Due to HSV**—It may occur with or without corneal disease, and iris atrophy is present. Treatment includes:

- Topical steroids: Steroids should never be used in presence of active epithelial keratitis.
- Cycloplegics.
- Systemic acyclovir: 400 mg 5 times a day.

**Due to VZV**: Anterior uveitis affects patients with HZO, particularly when vesicular eruption (rash) is present on the tip of nose (**Hutchinson sign**). The rash on the tip of nose is due to the involvement of the branch of nasociliary nerve. Anterior uveitis in HZO usually manifests 10 to 25 days after the onset of rashes. It is usually mild and asymptomatic and may be associated with sectorial iris atrophy. Treatment includes administration of topical steroids and cycloplegics.

**Complications of anterior uveitis:**

- Secondary glaucoma due to associated trabeculitis resulting in trabecular obstruction.
- Complicated cataract.
- Iris atrophy which is sectorial and thought to be due to occlusive vasculitis.
- Damage to sphincter pupillae.

**Acute Retinal Necrosis (ARN)**

It is a rare necrotizing retinitis caused by HSV in younger patients and VZV in older ones. In this condition, anterior granulomatous uveitis and vitritis are universal. Peripheral periarteritis progresses to involve full thickness of retina, leading to retinal necrosis and rhegmatogenous retinal detachment. Posterior pole is usually spared, so visual acuity remains fairly good.

**Treatment:** Includes IV acyclovir 10 mg/kg every 8 hours for 10 to 14 days, followed by oral acyclovir 800 mg 5 times a day for 6 to 12 weeks. This may arrest the disease and reduce the risk of involvement of the fellow eye but it does not prevent retinal detachment. Prognosis is relatively poor as a result of retinal detachment and ischemic optic neuropathy.

**Progressive Outer Retinal Necrosis (PORN)**

It is caused by VZV. It is a rare necrotizing retinitis seen in patients with immunosuppression due to AIDS or immunosuppressive drugs. The necrotizing retinitis is devastating because of immunosuppression of patient. The infection is limited only to outer retina in early stages and there is rapid progression to full-thickness retinal necrosis. PORN affects posterior pole and

outer retinal layer. Involvement of posterior pole in PORN results in early macular involvement, leading to rapidly progressive visual loss and minimal anterior uveitis. Involvement of outer retinal layers results in multifocal, yellow–white retinal infiltrates with minimal vitritis.

Rapid progression of disease due to immunosuppression causes full-thickness retinal necrosis and vitritis. So, vitreous inflammation is usually late and reflects extensive retinal necrosis.

It is diagnosed by vitreous samples for PCR and diagnostic assay of VZV DNA. Treatment includes IV ganciclovir alone or in combination with foscarnet. Thus, the basic difference between ARN and PORN is as given in **Table 9.10**.

**Cytomegalovirus (CMV) Retinitis**

CMV is an opportunistic pathogen in patients with impaired immune system due to AIDS or immunosuppressives (for leukemia and lymphoma, following organ transplantation).

**Ocular Manifestations**

CMV retinitis is the most common infection in AIDS. It is a chronic diffuse exudative infection of retina and characterized by yellow–white exudates in retina, representing the areas of retinal necrosis (necrotizing retinitis). It is associated with:

- Vasculitis with perivascular sheathing.
- Retinal hemorrhages.
- Vitreous exudates.

The infective process spreads slowly along retinal blood vessels to involve entire fundus and leads to total retinal atrophy.

**Table 9.10** Difference between acute retinal necrosis and progressive outer retinal necrosis

Acute retinal necrosis	Progressive outer retinal necrosis
<ul style="list-style-type: none"> <li>• It tends to start in periphery so macula is usually spared and cause anterior granulomatous uveitis</li> </ul>	<ul style="list-style-type: none"> <li>• Its affects posterior pole so there is early macular involvement and so anterior uveitis is minimal</li> </ul>
<ul style="list-style-type: none"> <li>• It involves full thickness of retina so results in vitritis and peripheral periarteritis</li> </ul>	<ul style="list-style-type: none"> <li>• It affects outer retinal layers; hence it causes minimal intraocular inflammatory signs of vitritis in early stages</li> </ul>
<ul style="list-style-type: none"> <li>• Vision: As macula is spared, visual acuity remains fairly good</li> </ul>	<ul style="list-style-type: none"> <li>• Because of early macular involvement, there is rapidly progressive visual loss</li> </ul>

### Treatment

- IV ganciclovir in the dosage of 5 mg/kg every 12 hours for 2 to 3 weeks, followed by 5 mg/kg every 24 hours for long term. Its side effect is bone marrow suppression.
- IV foscarnet: 60 mg/kg every 8 hours for 2 to 3 weeks, followed by 90 mg/kg every 24 hours for long term. Its side effects are nephrotoxicity and electrolyte disturbance.
- Implantation of ganciclovir slow-release device into vitreous. The implant is sutured to sclera and suspended in vitreous cavity. Its duration of efficacy is 8 months and it is superior to IV therapy with ganciclovir/foscarnet.

A combination of three or four antiretroviral drugs is known as highly active antiretroviral therapy (**HAART**) and acts at different stages of the HIV lifecycle. Side effects of HAART are bone marrow suppression and nephrotoxicity.

## Spirochaetal Uveitis

### Syphilis

It is *caused by* a spirochete, *Treponema pallidum*, and may be congenital or acquired. Syphilis affects both anterior and posterior uvea. In **congenital syphilis**, fetus acquires infection from infected mother via placenta. It is usually bilateral. Anterior uveitis and interstitial keratitis are common in congenital syphilis. Fundus shows bilateral pigmentary retinopathy (**salt and pepper fundus**). The fundus picture may mimic retinitis pigmentosa.

In adults, syphilis is usually sexually acquired. The *stages of acquired syphilis* in an untreated patient are primary, secondary, latent, and tertiary.

### Ocular Manifestations

Eye involvement occurs during secondary and tertiary stages. Occasionally, it may be seen during primary syphilis.

Anterior uveitis occurs in the secondary stage of syphilis. It may be *granulomatous* or

*nongranulomatous*. In some cases, iridocyclitis is first associated with dilated iris capillaries termed roseolae, possibly due to treponemal emboli. These roseolae may develop into localized papules and subsequently into larger yellowish, heavily vascularized nodules near pupillary and ciliary border of iris (*but not in intermediate region*) called gummas (**gummatous iridocyclitis**). These are associated with exudation and broad synechia. Posterior uveitis may occur as:

- *Acute syphilitic chorioretinitis* which is characterized by yellow placoid lesions, especially in the macular area. This is almost always associated with severe vitritis.
- *Chronic syphilitic chorioretinitis* which consists of depigmented retinal lesions, with pigment aggregated in corpuscles and attenuated vessels, and atrophy of optic disc resembling retinitis pigmentosa. *Symptoms include* defective central vision, night blindness, and irregular and concentric contraction of field and metamorphopsia. Neuroretinitis and periphlebitis are also common. Syphilitic infection is more severe and has a more aggressive course in HIV infection and responds less and slowly to conventional treatment. *It is recommended that tests for both HIV and syphilis be performed if either is found to be positive.*

### Differential Diagnosis

It must be differentiated from uveitis due to TB, sarcoidosis, autoimmune disease and serpiginous choroidopathy.

### Diagnosis

Following investigations are required to ascertain the diagnosis of syphilis:

- VDRL and RPR: These are nontreponemal tests and detect antibody to lecithin or cardiolipin which is a cholesterol antigen. These tests have lower specificity.
- FTA-ABS test and treponemal hemagglutination test: These are treponemal antibody tests which detect antibodies

against treponemal antigens and are more specific.

- Cerebrospinal fluid (CSF) examination for evidence of neurosyphilis is done in all cases of ocular syphilis.

### Treatment

Penicillin is used in all stages of syphilis. One of the following regimens may be used:

- IV aqueous penicillin G: 12 to 24 mega units/day for 14 days.
- IM procaine penicillin: 2 to 4 mega units/day for 14 days.

It is supplemented with oral probenecid 2 g daily. It increases and prolongs plasma level of penicillin. Patients sensitive to Penicillin are treated with:

	<b>Oral tetracycline</b>	– 500 mg q.i.d. for 30 days
or	Oral doxycycline	
or	Oral erythromycin	– 500 mg q.i.d. for 30 days

## Fungal Uveitis

Fungal uveitis may be:

- Exogenous following penetrating injury with vegetable matter or after intraocular surgery.
- Endogenous transmitted via blood from focus elsewhere in the body.

It may be due to *Histoplasma capsulatum*, *Candida albicans*, *Coccidioides immitis*, or *Cryptococcus*.

## Presumed Ocular Histoplasmosis Syndrome (POHS)

It is caused by *Histoplasma capsulatum*. Patients with POHS show an increased prevalence of HLA-B7 and HLA-DR2.

### Ocular Manifestations

If there is no macular involvement, the patient is asymptomatic. With macular involvement, metamorphopsia occurs. Intraocular inflammation

is absent, that is, vitreous cells are not seen in POHS. Types of fundus lesions seen in POHS are:

- Atrophic “punched-out” chorioretinal scars (called **histospots**) are seen in midretinal periphery and posterior pole. These probably represent the healed benign histoplasma lesions of childhood.
- Peripapillary atrophy.
- Macular lesion as exudative maculopathy–Atrophic macular scar causes a hole in the Bruch’s membrane with ingrowth of capillaries. It results in development of subretinal choroidal neovascularization and leakage from choroidal new vessels (**CNV**), causing **serous macular detachment**. Serous macular detachment causes visual symptoms (metamorphopsia and decreased central vision), which may regress if fluid gets absorbed spontaneously. It may be complicated by subretinal bleeding from CNV (**hemorrhagic disciform maculopathy**).

### Diagnosis

It is confirmed by the histoplasma skin test.

### Treatment

Treatment of CNV is done with argon laser photocoagulation. In extrafoveal CNV, treatment is rewarding, while in subfoveal CNV, prognosis is poor.

## Candidiasis

It is caused by *Candida albicans*, a frequent commensal of mucous membranes of mouth, gastrointestinal tract (GIT), and vagina. *Candida* is an opportunistic nonpathogenic fungus. So, candidiasis occurs when immunity is compromised in patients receiving immunosuppressive therapy, and in patients afflicted with AIDS or diabetes. Hematogenous spread occurs from GIT to involve the eye.

### Ocular Manifestations

Chorioretinitis with overlying vitritis–Multiple, round, white, slightly elevated lesions with

indistinct borders (**cotton ball-like**) develop in retina. These may be associated with retinal hemorrhages. If antifungal therapy is not instituted, these small retinal lesions enlarge and extend into vitreous, giving rise to floating “cotton ball” colonies which may join together to form a “**string of pearls**.”

#### Treatment

It includes IV amphotericin B or pars plana vitrectomy + intravitreal amphotericin B.

### Parasitic Uveitis

- Toxoplasmosis.
- Toxocariasis.
- Onchocerciasis.
- Cysticercosis.

### Toxoplasmosis

It is caused by *Toxoplasma gondii*, an obligate intracellular protozoan parasite. It has a particular affinity for neural tissues, so it primarily involves CNS and retina. Cats are the definitive hosts of the parasite which excrete oocytes in their feces. Transmission of trophozoites (active form responsible for tissue destruction and the inflammation) via placenta causes infestation of fetus in a pregnant woman. *If mother is infested before pregnancy, fetus will not be affected.* Ocular involvement can be congenital (congenital toxoplasmosis) or acquired (acquired toxoplasmosis).

### Congenital Toxoplasmosis

In congenital toxoplasmosis, ocular lesion is usually associated with encephalitis. Inflammatory reaction is more severe in congenital form.

#### Ocular Features

Parasite causes granulomatous retinochoroiditis which is typically necrotic (necrotizing retinochoroiditis). The lesions are bilateral and particularly involve the macular area. In necrotizing retinochoroiditis, entire thickness of retina and choroid is destroyed, resulting in bilateral punched out, heavily pigmented scar, especially in the macular area (**Fig. 9.21**) which causes defective vision. The lesions resemble macular coloboma.

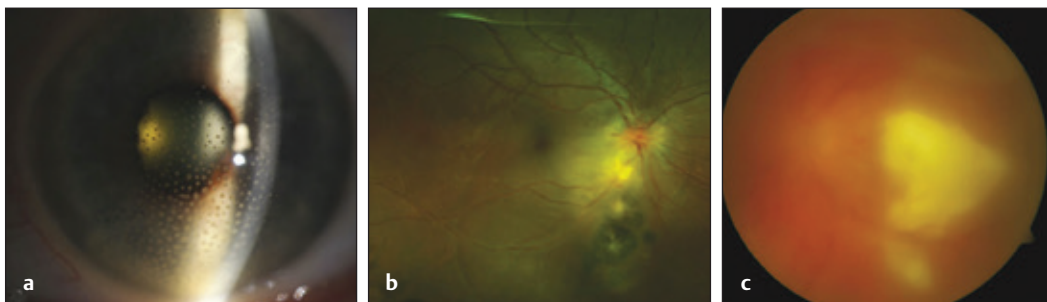
*Encephalitis* leads to convulsions. If the infants survive, they show areas of intracranial calcification in brain and mental retardation.

So, the **characteristic triad (three C's)** of congenital toxoplasmosis is:

- Convulsions.
- Chorioretinitis.
- Calcification in brain.

### Acquired Toxoplasmosis

In adults, ocular infestation can be the result of reactivation of congenital infestation or it can be acquired postnatally. Reactivation of healed lesion is quite common, often at the edge of previous scar. In acquired toxoplasmosis, ocular



**Fig. 9.21 (a–c)** Ocular toxoplasmosis. Source: Exam Findings. In: Ehlers J, ed. The Retina Illustrated. 1st Edition. Thieme; 2019.

involvement is usually unilateral, mild, and without CNS involvement.

**Reactivation of healed lesion** (recurrence): The necrotic retina has encysted parasites at the edge of previous scar. The periodic rupture of cysts releases trophozoites into normal retinal cells. It causes secondary immunological reaction, resulting in fresh lesions commonly at the margins of old scar.

The *primary lesion* is retinitis associated with posterior uveitis, that is, retinochoroiditis. It is usually associated with severe vitritis due to exudation into vitreous with overlying vitreous haze.

#### Clinical Presentation

It presents as unilateral, sudden onset of floaters, blurred vision and photophobia. Focal retinitis is present which is characterized by yellow–white lesion with fluffy indistinct margins adjacent to the edge of an old inactive pigmented scar (“**satellite lesion**”). The lesion is most commonly solitary. There is also an overlying vitreous haze.

#### Investigations

- Sabin–Feldman dye test.
- ELISA test for IgG and IgM.
- Indirect hemagglutination test (IHA).
- Immunofluorescent antibody test.

#### Treatment

Steroids are given in conjunction with antimicrobials.

- **Corticosteroids:** Oral prednisolone—1 mg/kg/day initially, then tapered according to the clinical response.
- **Antimicrobials:** Sulphatriad (sulphadiazine + sulphathiazole + sulphamerazine) is given in dosage of 1 g every 6 hours for 4 weeks.

#### Alternatively,

- ◇ Cotrimoxazole is a combination of trimethoprim 160 mg + sulphamethoxazole 800 mg is given b.i.d. for 4 to 6 weeks. Side effects of cotrimoxazole

are renal stones and Stevens–Johnson syndrome.

- ◇ Pyrimethamine: Loading dose is 75 to 150 mg followed by 25 mg daily for 3 to 4 weeks. It is a *folic acid antagonist*, so it may cause thrombocytopenia and leucopenia. Therefore, weekly complete blood counts and platelet counts must be done. It is given in combination with oral folic acid 10 mg/day.

**Pyrimethamine is avoided in AIDS** due to preexisting bone marrow suppression and the antagonistic effect of zidovudine when given with pyrimethamine.

- ◇ Clindamycin (300 mg q.i.d. for 4 weeks) and sulphadiazine (1 g q.i.d. for 3–4 weeks): These act synergistically. Clindamycin causes clostridial overgrowth and may cause colitis. Sulphadiazine (a sulphonamide) inhibits clostridial overgrowth, so risk of colitis is reduced when clindamycin is used together with a sulphonamide.

Corticosteroids should always be used in conjunction with one or more of the above antimicrobials. If medical measures fail, photocoagulation is done.

#### Toxocariasis

It is *caused by Toxocara canis* (an intestinal roundworm of dogs) and *Toxocara cati* (an intestinal roundworm of cats). Children who play with dogs or cats are at particular risk of acquiring the disease.

#### Ocular Manifestations

*Ocular toxocariasis* is almost always unilateral and can present as one of the following ocular lesions:

- **Chronic Endophthalmitis:** It presents as **leucocoria** between the age of 2 to 9 years. So, it mimics retinoblastoma.
- **Posterior pole granuloma:** Granuloma consists of eosinophils and IgE. It appears as a white lesion and protrudes into the eye from retinal tissue.

- Peripheral granuloma.
- Localized vitreous abscess.

Diagnostic test is ELISA.

#### Treatment

It includes systemic corticosteroids and pars plana vitrectomy. Indications of pars plana vitrectomy are endophthalmitis and vitreoretinal traction. Antihelminthic drugs are of minimal value and may even result in increased inflammation due to death of toxocara organism.

### Onchocerciasis (River Blindness)

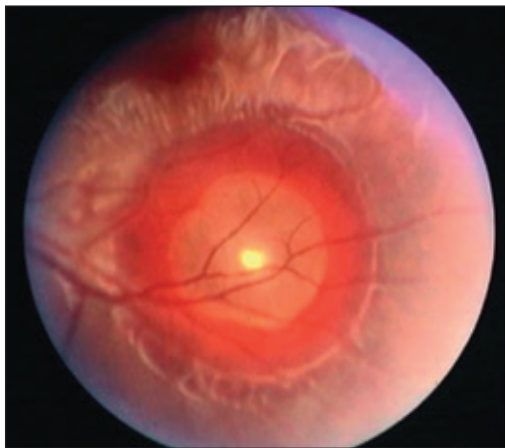It is caused by *Onchocerca volvulus*, a filarial nematode. It is transmitted by the bite of black fly simulium (vector). Ocular features include punctate keratitis, sclerosing keratitis, anterior uveitis, floating microfilariae in aqueous, chorioretinitis, usually bilateral, and optic atrophy. Diagnosis is achieved by biopsy of skin nodules. Ivermectin is a very effective drug for its treatment.

### Cysticercosis

It is caused by *Cysticercus cellulosae*, the larvae form of pork tape worm, *Taenia solium*.

#### Ocular Manifestations

It presents as subconjunctival cysts. Larvae may be found in vitreous or subretinal space (**Fig. 9.22**).



**Fig. 9.22** Subretinal cysticercus.

Live cysticercus (larvae) cause little reaction but dead larva release toxins which produce intense inflammation.

#### Investigations

As the disease often involves lungs, muscles, and brain, so the following investigations are performed:

- X-ray chest and muscle—show calcified cysts.
- ELISA test.
- CT or MRI scan of head for accompanying cysticercus infection in brain. *Presence of cysticercus in the eye is diagnostic.*

#### Treatment

Medical treatment with **albendazole is not indicated** for ocular disease, since dead larvae may induce intense inflammation, leading to loss of vision. Treatment of choice is surgical removal of cysts. Subretinal cysts may be removed transsclerally and intravitreal cysts are removed by vitrectomy.

### Immunological Uveitis

#### Ankylosing Spondylitis

It is a chronic, inflammatory arthritis characterized by calcification and ossification of ligaments, and capsules of joints, leading to progressive stiffening and fusion of axial skeleton. It **involves axial skeleton** (sacro-iliac joint and posterior intervertebral joints). **HLA-B27** antigen is strongly associated with the disease. Males are more affected than females. It affects people between 20 to 40 years of age.

#### Clinical Features

It presents with pain and morning stiffness in the lower back in early adulthood. Arthritis is also seen mostly affecting sacro-iliac joints and spine. The spine becomes fixed in flexion with reduced mobility of thoracic cage. *Acute anterior uveitis* occurs, which is often unilateral, recurrent, and nongranulomatous. Bilateral simultaneous involvement is rare.



### Investigations

Following investigations help in reaching a diagnosis:

- ESR is raised.
- Radiology: X-ray sacro-iliac joints reveals sclerosis and ossification. Spinal ligaments are also ossified and called “**bamboo spine.**”
- Tissue typing: HLA-B27 is positive in 95% cases.

### Treatment

It is treated as usual anterior uveitis, that is, by steroids (topical and systemic) and topical cycloplegics.

### Complications

Complicated cataract and glaucoma are the usual complications of ankylosing spondylitis.

## Juvenile Chronic Arthritis (JCA)

It is a chronic inflammatory arthritis occurring before the age of 16 years.

### Classification

JCA can be classified as pauciarticular onset JCA, polyarticular onset JCA, and systemic onset JCA. *The term **Still's disease** is reserved for patients with systemic onset disease.*

### Ocular Manifestations

Anterior uveitis in JCA is fairly rare with **polyarticular JCA**. Uveitis itself is not common but is seen as a complication of scleritis. It is extremely rare in **systemic onset JCA** (Still's disease). It develops in **pauciarticular JCA** which is bilateral usually, chronic, of insidious onset and nongranulomatous with minimal signs.

### Treatment

Treatment is done by the following:

- Topical steroids.
- Periocular steroids: When there is poor response to topical steroids
- Methotrexate in low dose: When there is steroid resistance.

### Complications

Band keratopathy, cataract and secondary glaucoma are the usual complications of juvenile chronic arthritis.

## Reiter's Syndrome

It is also known as **reactive arthritis** and characterized by the triad of urethritis (nongonococcal), conjunctivitis, and arthritis. Conjunctivitis follows urethritis and precedes arthritis. It affects mostly young males and is associated with **HLA-B27**.

### Ocular Manifestations

- Conjunctivitis: It is bilateral and mucopurulent.
- Acute anterior uveitis: It occurs in 12% cases and is nongranulomatous.
- Keratitis as punctate subepithelial keratitis.

### Treatment

Chlamydia have been isolated from urethral discharge in 50% of cases. For urethritis in Reiter syndrome, oral tetracycline 500 mg q.i.d. for 3 to 6 weeks is given. For uveitis, steroids and cycloplegics are given.

## Behçet Syndrome

It is an idiopathic multisystem disease characterized by severe uveitis with hypopyon, ulcerative lesion in conjunctival, oral and genital mucosae, neurological manifestations, and articular manifestations. It is strongly associated with **HLA-B51**. It is seen in young adults and rarely presents in childhood or old age. Etiology is unknown. Basic lesion is probably caused by immune complexes.

### Ocular Manifestations

These are usually bilateral. The disease involves:

- *Anterior segment* and manifests as acute anterior uveitis, which is bilateral, nongranulomatous and recurrent.

Uveitis is usually associated with a transient, mobile hypopyon. Hypopyon shifts with gravity as the patient changes head position.

- *Posterior segment* lesions include retinal vasculitis: It may involve both veins and arteries and result in occlusion (**obliterative vasculitis**). Retinal vasculitis leads to vascular leakage, which gives rise to **diffuse retinal edema** involving outer retinal layers, **CME** and **disc edema**.

### Treatment

There is no specific treatment. Important points of consideration are:

- Systemic steroids shorten the duration of inflammation.
- Immunosuppressives are suitable for long-term therapy.

### Prognosis

It has poor visual prognosis.

## Vogt–Koyanagi–Harada (VKH) Syndrome

It is a rare condition which typically affects pigmented races (Asians and Africans).

### Etiology

The *cause* is unknown, but it may be an autoimmune response to melanocytes. So, it causes inflammation of melanocyte-containing tissues such as uvea, ears, skin and meninges. The disease is associated with **HLA-DR 1** and **HLA-DR 4** which suggests an immunogenic predisposition. Originally, VKH syndrome was categorized as **Vogt Koyanagi disease**, which is characterized by skin changes (poliosis, vitiligo, and alopecia), chronic anterior uveitis, and **Harada disease**, which is characterized by bilateral posterior uveitis with exudative retinal detachment and neurological features. Now, the two entities are clubbed together as VKH syndrome.

### Ocular Manifestations

Ocular features in VKH syndrome include:

- Chronic granulomatous anterior uveitis.
- Posterior uveitis (exudative choroiditis).

- Exudative retinal detachment.
- Depigmentation of fundus lesions (“**sunset glow**” fundus).

### Extraocular Features

Inflammation of melanocyte-containing tissues in VKH syndrome affects meninges, skin and ear. *Neurological signs* due to the involvement of meninges include neck stiffness, convulsions, paresis and cranial nerve palsies. *Cutaneous signs* include alopecia (baldness), poliosis (whitening of eyebrows, eye lashes and hair) and vitiligo (patch of skin depigmentation). *Auditory features* include tinnitus, vertigo, and deafness.

*Neurological and auditory features occur in the prodromal phase of the disease. Uveitis phase occurs within 1–2 days after onset of neurological signs. Skin findings do not precede onset of CNS or ocular disease.*

### Treatment

Posterior segment involvement is treated with:

- IV steroids: Methyl prednisolone 1 g/day in infusion bottles for 3 days, followed by high-dose oral steroids tapered over months.
- In steroid-resistant cases: Immunosuppressive drugs (cyclosporin and cyclophosphamide).

## Miscellaneous Uveitis

### Glaucomatocyclitic Crisis (Posner–Schlossman Syndrome)

It is characterized by acute recurrent, mild anterior uveitis associated with raised IOP (secondary glaucoma). The condition is probably due to an accompanying trabeculitis. Inflammation is minimal with no aqueous flare, fine and nonpigmented KPs, no posterior synechiae, and no peripheral synechiae.

Glaucoma is out of proportion to the inflammation and presents with very high IOP (40–60 mm Hg), epithelial edema due to raised IOP, halos in a white eye, and open-angle and

unilateral glaucoma. Patients present with diminution of vision and halos around light.

#### Treatment

Topical steroids are commonly given. Control of IOP is done by timolol maleate and systemic carbonic anhydrase inhibitors.

### Fuchs Heterochromic Iridocyclitis

It is a chronic, low-grade anterior uveitis of insidious onset. It presents with the following signs:

- KPs:
  - ◇ Small and white: They never become confluent or pigmented.
  - ◇ Round and scattered throughout the corneal endothelium. Presence of KPs distinguish the condition from congenital heterochromia.
- Aqueous: Cells are often present.
- Iris: Absence of posterior synechiae.
  - ◇ *Diffuse atrophy of iris stroma* lead to:
    - Atrophy of sphincter pupillae resulting in *mydriasis*.
    - Prominent radial iris blood vessels.
    - Loss of iris details resulting in *washed-out appearance* of iris.
  - ◇ Heterochromia iridis: It is an important and common sign.
- Neovascularization of angle of anterior chamber on gonioscopy. So, when paracentesis is done, pressure in anterior chamber is suddenly reduced. These new vessels bleed, and fine filiform hemorrhage occurs from the opposite angle. This is known as **Amsler sign**.

#### Treatment

- Posterior subtenon injection of triamcinolone.
- Topical steroids.
- *As posterior synechiae do not develop*, mydriatics are not required.

#### Complications

Cataract and glaucoma are usual complications of Fuchs heterochromic iridocyclitis.

### Lens-Induced Uveitis

It is an immune response to **lens proteins** (antigen) following rupture of lens capsule. It is caused by trauma and incomplete cortical aspiration in extracapsular cataract extraction (ECCE). It may present as phacoanaphylactic uveitis and phacogenic uveitis. It presents with blurred vision and pain. Clinical signs seen in a patient include granulomatous anterior uveitis, raised IOP, and lens matter in anterior chamber.

#### Treatment

Removal of all lens matter followed by topical and systemic steroids.

### Endophthalmitis

Endophthal (inner eye) itis (inflammation) is an intraocular inflammation involving uveal tissue, retina, vitreous, and anterior chamber. It involves all intraocular structures except sclera. Endophthalmitis is classified into two groups: **infective** (bacterial or fungal) **and noninfective** (sterile). **Infective** endophthalmitis may be **exogenous** (due to exogenous infection elsewhere) or **endogenous** (due to endogenous infection during intraocular surgery). **Noninfective** endophthalmitis may be due to:

- Retained lens matter (induced by lens proteins).
- Toxic material introduced in the body.

### Bacterial Endophthalmitis

It may be exogenous and endogenous. Exogenous endophthalmitis may be postoperative or posttraumatic. *Source of infection in postoperative endophthalmitis may be eyelids, conjunctiva and lacrimal sac.* Microbes can enter the eye through the filtering bleb after glaucoma surgery. It can develop one to several days after surgery.

In endogenous endophthalmitis, organisms enter the eye through blood stream from the infected focus elsewhere in the body. Risk factors include:

- Diabetes mellitus.

- Patient's receiving steroids or immunosuppressives.
- Meningococcal septicemia.
- AIDS.
- IV drug abusers.
- Urinary tract infection (UTI) (*E. coli*).
- Endocarditis.

## Causative Pathogens

Causative pathogens in bacterial endophthalmitis are:

- *Staphylococcus* (*S. aureus* and *S. epidermidis*).
- *Streptococcus*.
- *Pneumococcus*.
- *Pseudomonas pyocyanea*.
- *Klebsiella*.
- *E. coli*.
- *Bacillus cereus* especially in IV drug abusers.

The anaerobe propionibacterium acnes produce chronic, low-grade infection and causes delayed onset postoperative endophthalmitis.

## Clinical Features

Symptoms of bacterial endophthalmitis include pain, blurred vision, floaters, redness, photophobia, headache, and fever (it is more common with endogenous infection).

Signs of bacterial endophthalmitis include:

**Anterior segment:**

- Lids: Swollen lids.
- Conjunctiva: Circumcorneal congestion.
- Cornea: Corneal edema.
- AC: Hypopyon in severe cases and soon becomes full of pus.
- Iris: Anterior fibrinous uveitis.

**Posterior segment:** Vitreous becomes purulent. Vitreous abscess shows yellow reflex with oblique illumination, and normal red fundus reflex is lost.

In severe cases, destruction of ciliary processes causes decrease in IOP and shrinkage of eyeball.

## Investigations

The following investigations help in the diagnosis of bacterial endophthalmitis:

- Complete blood count.
- Blood sugar.
- Urine.
- X-ray chest.
- Aqueous and vitreous tap for:
  - ◇ Smears which are examined by Gram and Giemsa staining.
  - ◇ Cultures on blood and chocolate agar media.
- Blood culture.

## Treatment

It includes the use of antibiotics and steroids and then vitrectomy.

### Antibiotics

A combination of antibiotics must be used to cover all organisms. Every possible route of administration should be used (intravitreal, topical, subconjunctival, and systemic).

1. **Intravitreal antibiotics** are the treatment of choice. Intravitreal antibiotics are injected after taking a 0.2 to 0.3 mL vitreous aspirate. Vitreous aspirate is used for smears and culture. The regimen to be followed is given below:

Vancomycin +	1 mg in 0.1 mL (for Gram positive cocci)
Ceftazidime	2.25 mg in 0.1 mL (for Gram negative organisms)
<b>Or</b>	
Vancomycin + Amikacin/ Gentamicin	1 mg in 0.1 mL 0.4 mg in 0.1 mL (for Gram negative organisms)

2. **Topical antibiotics:**

Eye drops	Fortified cefazolin/ Vancomycin	are used every 1 hour
+	Gentamicin/ Amikacin	
They are instilled along with cycloplegics: Atropine 1% or Homatropine 2%		
+		
steroid eye drops—dexamethasone or predacetate		

### 3. Subconjunctival antibiotics:

Vancomycin	25 mg in 0.5 mL
+	
Ceftazidime	100 mg in 0.5 mL
These are used along with subconjunctival dexamethasone 6 mg in 0.25 mL.	

### 4. Systemic antibiotics (for systemic infections):

Combination of vancomycin	1 g	every 12 hours	are given intravenously
+			
Ceftazidime	1 g	every 12 hours	

Steroids should be withheld where there is strong suspicion of a fungal etiology.

### Corticosteroids

There exist two views on the use of steroids: Some recommend use of steroids along with antibiotics from the outset, while others prefer to wait for control of infection by antibiotics therapy and start steroids 24 to 48 hours after the antibiotic therapy. They exert anti-inflammatory effect, so limit the inflammatory damage to intraocular structures.

They can be used either topically (dexamethasone/prednisolone acetate eye drops) or subconjunctivally (dexamethasone injection 0.4 mg in 0.1 mL is optional).

### Pars Plana Vitrectomy

- **Indications:**
  - ◇ If visual acuity is light perception or worse.
  - ◇ If patient does not respond to intravitreal antibiotics within 48 hours.
- **Advantages:**
  - ◇ It helps in recovery by removing infected vitreous.
  - ◇ Vitrectomy allows better antibiotic penetration following intravitreal injection.

- ◇ It provides vitreous for smear and culture (**Flowchart 9.4**).

## Fungal Endophthalmitis

It may be exogenous or endogenous. **Exogenous** occurs after intraocular surgery or injury with vegetable matter. It is usually caused by filamentous fungi such as *Aspergillus*, *Fusarium*, and *Penicillium*. **Endogenous variety** is metastatic in origin and from a focus within the body. Risk factors are immunosuppression, IV drug abuse and chronic lung disease such as cystic fibrosis. It is most commonly caused by *Candida albicans* and *mucor* (**Flowchart 9.4**).

The progression is much slower and usually manifests within 3 months after surgery.

### Clinical Features

*Exogenous fungal endophthalmitis* usually affects anterior vitreous and anterior uvea with formation of hypopyon.

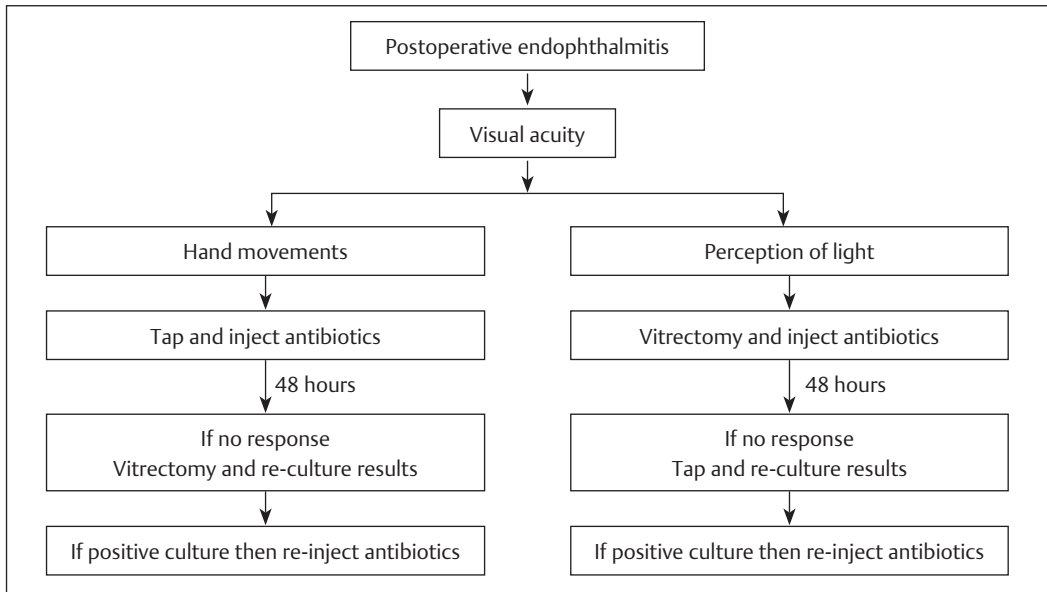
*Endogenous fungal endophthalmitis* causes chorioretinal lesions with overlying vitritis and floating “cotton ball” colonies seen after extension into vitreous.

### Investigation

Anterior chamber and vitreous taps—Smear and culture samples inoculated onto **Sabouraud medium**.

### Treatment

Treatment includes drugs and vitrectomy. **Drug of choice:** Amphotericin B given systemically in IV drip and by intravitreal injection 5 µg in 0.1 mL. Additional oral antifungal agents like fluconazole, ketoconazole, and flucytosine should be given. In fluconazole-resistant candida and fusarium infections, oral voriconazole is given. Systemic steroids are contraindicated in fungal infections. Pars plana vitrectomy with intravitreal Amphotericin B (5 µg in 0.1 mL) is also used.



**Flowchart 9.4** Algorithm for management of endophthalmitis after cataract extraction.

## Panophthalmitis

Panophthal (whole eye) itis (inflammation) involves the entire globe. Thus, it is similar to endophthalmitis, except that inflammation also involves outer coat of eye and Tenon's capsule. In severe cases, orbital tissues may also be affected. It usually starts as purulent anterior or posterior uveitis and soon involves the whole eye.

## Etiology

The following may occur:

- Penetrating ocular injury/postoperative infections (**exogenous** panophthalmitis).
- Infective embolus in retinal or choroidal vessel causing **endogenous** panophthalmitis.

*Causative organisms* are identical for infective bacterial endophthalmitis:

- *Pneumococcus*.
- *Staphylococcus*.
- *Streptococcus*.
- *Pseudomonas pyocyanea*.
- *Escherichia coli*.

## Clinical Features

**Symptoms include** severe ocular pain, headache and sometimes vomiting, fever, loss of vision, and redness and swelling of eyes.

Clinical signs are as follows:

Lids:

- Intense swelling.

Conjunctiva:

- Chemosis.
- Ciliary as well as conjunctival congestion.

Globe:

- Proptosis may be present.
- Painful and limited ocular movements due to involvement of Tenon's capsule.
- Tender.

Cornea: Cloudy and edematous.

Anterior chamber: Contains massive hypopyon.

IOP: Often raised.

Posterior segment—Purulent retinochoroiditis and vitreous become a bag of pus. Posterior segment cannot be visualized due to hazy media.

In severe cases, perforation of globe takes place usually near limbus and pus oozes out. Thus, pain subsides, IOP falls, and eyeball shrinks.

### Treatment

- Antibiotics:
  - ◇ Systemic.
  - ◇ Subconjunctival injections.
- Anti-inflammatory and analgesics.
- Evisceration to avoid risk of intracranial dissemination of infection.

In most cases, a **frill excision** (a collar of sclera is left around optic nerve) can be performed.

### Complications

If panophthalmitis is not adequately treated in time, infection may spread, leading to orbital cellulitis and consequently cavernous sinus thrombosis. Infection may spread to optic nerve sheath, resulting in meningitis.

### Pigment Dispersion Syndrome

It is usually a bilateral condition characterized by the liberation of pigment from iris pigment epithelium. The liberated pigment is deposited throughout the anterior segment. Pathogenesis of pigment dispersion syndrome is explained in **Flowchart 9.5**.

### Clinical Features

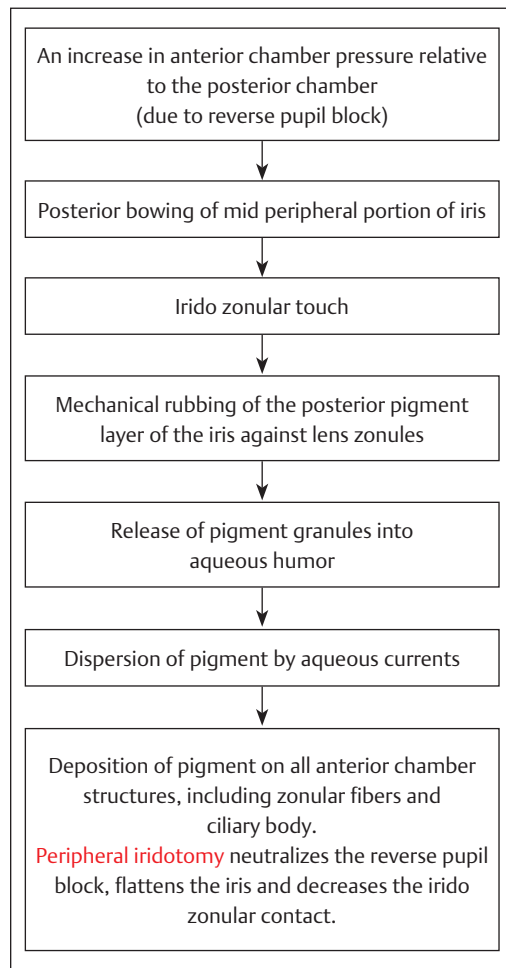
It affects cornea, iris, and the angle of anterior chamber.

- Cornea: There is pigment deposition on corneal endothelium in vertical spindle-shaped distribution (**Krukenberg spindle**).
- Iris: Pigment epithelial atrophy of iris gives rise to characteristic radial slit-like defects. Partial loss of pupillary frill is common.
- Angle of anterior chamber: There is a wide open angle. Also, there is characteristic midperipheral iris concavity that may increase with accommodation. Trabecular hyperpigmentation is also seen. Pigmentary obstruction of intertrabecular spaces causes rise in IOP.

### Degenerative Changes in Uveal Tract

Degenerative changes in uveal tract may involve iris or choroid. Degenerative changes in **iris include** essential (progressive) atrophy of iris and iridoschisis. Degenerative changes in choroid could be either primary or secondary. Primary degenerations are localized or general. Localized primary degenerations include:

- Central areolar choroidal atrophy.
- Myopic chorioretinal degeneration.
- Central guttate choroidal atrophy (Tay choroiditis).



**Flowchart 9.5** Pathogenesis of pigment dispersion syndrome.

General primary degenerations include:

- Gyrate (essential) atrophy of choroid.
- Choroideremia.

## Degenerative Changes in Iris

### Essential Atrophy of Iris

It is often unilateral and progressive and affects young females. Etiology is unknown. Because of its progressive nature, a large portion of uveal tissue completely disappears with the development of multiple holes in iris—**pseudopolyopia** (more than one pupil due to secondary holes in iris).

**Essential atrophy of iris** is a part of iridocorneal endothelial (**ICE**) syndrome. The common feature of ICE syndrome is an abnormal corneal endothelial cell layer which has the capacity to proliferate and migrate across the angle and on to the surface of iris. The down growth of endothelial layer across the angle causes onset of glaucoma and loss of vision. Contraction of membrane produces:

- Peripheral anterior synechiae.
- Ectropion uveae.
- Dyscoria (abnormal shape of pupil).
- Corectopia (displaced pupil or malposition of pupil).
- Prognosis is poor, but, fortunately, the disease is unilateral.

#### Iridocorneal endothelial syndrome (ICE syndrome)

ICE syndrome typically affects one eye of middle-aged women. It consists of three clinical entities:

- Progressive (essential) iris atrophy.
- Cogan–Reese syndrome (iris nevus).
- Chandler syndrome.
- Cogan–Reese syndrome (iris nevus) is characterized by dark brown pigmented nodules in the iris stroma.
- Chandler syndrome is associated with endothelial disturbances and corneal edema.

### Iridoschisis

It is the dehiscence of anterior mesodermal layers of iris. A cleft is formed between anterior and posterior part of iris stroma, with strands of anterior part floating into the anterior chamber. It occurs due to senile degenerative changes or may be a late manifestation of ocular trauma.

## Degenerative Changes in Choroid

These are more common than degenerative changes in iris and may be:

- Primary choroidal degenerations such as:
  - ◇ Central guttate choroidal atrophy (Tay choroiditis).
  - ◇ Central areolar choroidal atrophy.
  - ◇ Myopic chorioretinal degeneration.
  - ◇ Gyrate atrophy of choroid.
  - ◇ Choroideremia.
- Secondary choroidal degenerations.

### Primary Choroidal Degenerations

#### *Central Guttate Choroidal Atrophy (Tay Choroiditis)*

It is characterized by multiple, minute, yellowish-white spots in the macular area called colloid bodies (drusen). These are due to the presence of hyaline excrescences on the Bruch's membrane. The condition is bilateral and generally does not cause visual impairment.

#### *Central Areolar Choroidal Atrophy*

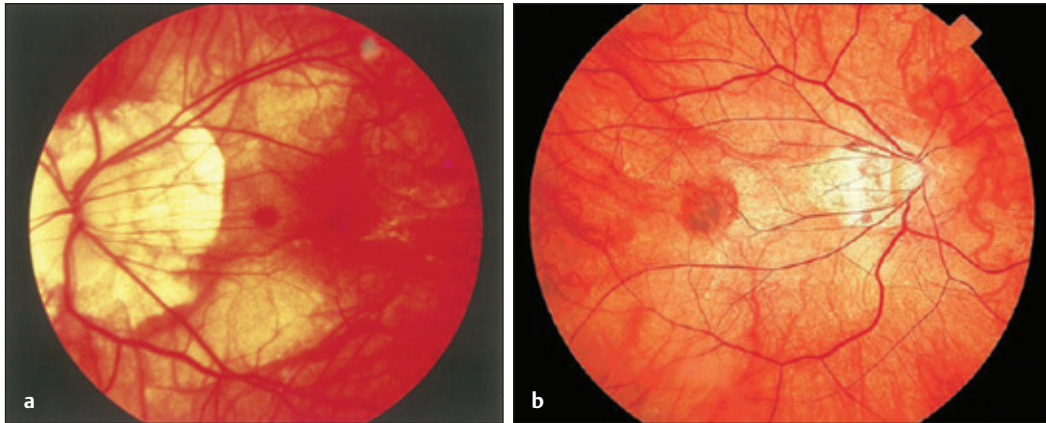
It is characterized by large circular patch of degeneration in the macular area, owing to retinal pigment epithelial (RPE) atrophy and loss of choriocapillaris at the macula. Choroidal vessels are visible in the degenerative patch. It is genetically determined with autosomal dominant inheritance. Prognosis is poor with severe visual loss.

#### *Myopic Chorioretinal Degeneration*

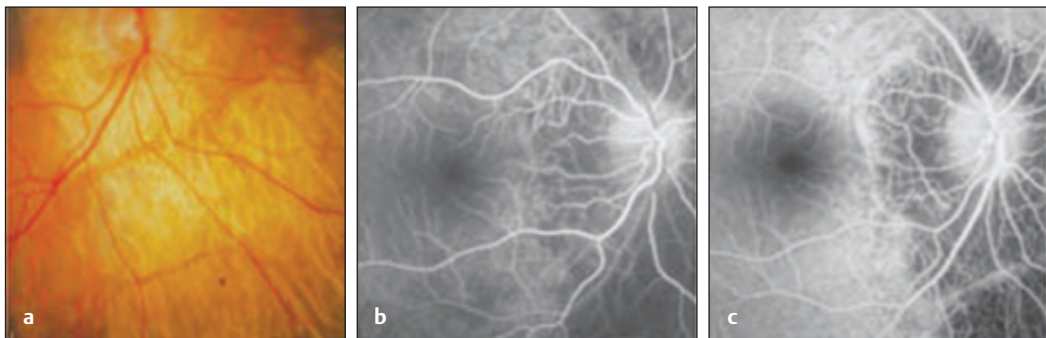
It is commonly seen in pathological myopia. Degenerative changes are more marked around the optic disc and central area of fundus. These include:

- Myopic crescent around temporal border of disc or formation of a complete ring around disc. It is essentially atrophic.
- Chorioretinal atrophy in the central area of fundus (**Fig. 9.23a**).
- Foster–Fuchs spot: This is a circular pigmented lesion developed after macular hemorrhage has been absorbed (**Fig. 9.23b**).





**Fig. 9.23** (a) Myopic chorioretinal degeneration. Source: Scott I, Regillo C, Flynn H et al., *Vitreoretinal Disease: Diagnosis Management, and Clinical Pearls*, 2nd Edition, 2017. (b) Fuchs Spot. Source: Myopia. In: Steidl S, Hartnett M, ed. *Clinical Pathways in Vitreoretinal Disease*. 1st Edition. Thieme; 2003.



**Fig. 9.24** (a–c) Gyrate atrophy of choroid. Source: Choroideremia and gyrate atrophy. In: Heimann H, Kellner U, Forrester M, ed. *Atlas of Fundus Angiography*. 1st Edition. Thieme; 2006.

- Lacquer cracks (linear breaks in the Bruch's membrane).

#### *Gyrate Atrophy of Choroid*

It is an inborn error of ornithine (amino acid) metabolism. The disease usually begins during the first decade of life. This condition is due to deficiency of enzyme **ornithine keto acid aminotransferase** (the main ornithine degradation enzyme). The deficiency of the enzyme results in an elevated ornithine level in plasma (ornithinemia), urine, CSF, and aqueous humor.

It is characterized by progressive atrophy of choroid and RPE with **macular sparing** (Fig. 9.24).

The patches of chorioretinal atrophy are in far and midretinal periphery, resulting in reduction of peripheral vision associated with night blindness. It has autosomal recessive inheritance. In this, electroretinogram (ERG) is subnormal or nonrecordable. Prognosis is generally poor.

#### *Treatment*

- Reduction in ornithine levels with an arginine-restricted diet.
- Pyridoxine (Vitamin B<sub>6</sub>) may normalize plasma and urinary ornithine levels.

#### *Choroideremia*

It has X-linked recessive inheritance with gene located on X-chromosome and affects only males

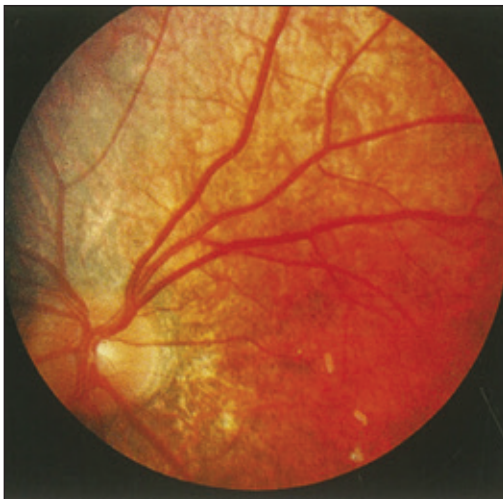with female carriers. Thus, an affected male cannot transmit the gene to his sons, and all the daughters of the affected father will be carriers.

### Clinical Presentation

It is characterized by progressive, diffuse degeneration of choroid, RPE and retinal photoreceptors, and presents in the first decade of life with defective night vision and depigmentation of RPE. Atrophy of choroid and RPE develop in the midperiphery and then spread centrally and toward periphery (Fig. 9.25). Because of midperipheral atrophy, the condition presents with defective night vision (as rods are more in periphery and mid periphery) and progressive constriction of visual fields. **Central vision is the last to be affected** as RPE under foveola may remain intact. At the end of the first decade, scotopic ERG is nonrecordable and photopic ERG is severely subnormal. Prognosis is very poor and causes blindness.

So, choroideremia is characterized by:

- Night blindness (nyctalopia).
- Progressive atrophy of choroid and RPE.
- Constriction of visual fields.



**Fig. 9.25** Choroideremia. Source: Scott I, Regillo C, Flynn H et al., Vitreoretinal Disease: Diagnosis Management, and Clinical Pearls, 2nd Edition, 2017.

## Secondary Choroidal Degenerations

These occur following inflammatory lesions (chorioretinitis), resulting in atrophy of choroid and outer retinal layers, with pigmentary changes.

**Ophthalmoscopically**, jet-black, branched pigment spots resembling bone corpuscles deposits in the perivascular spaces of veins. Thus, the picture resembles retinitis pigmentosa (pigmentary retinal dystrophy).

**In chorioretinal atrophy** (healed chorioretinitis), pigment resembles bone corpuscles but lie deep to retinal vessels, so retinal vessels can be traced over the pigmentary spots. **In retinitis pigmentosa**, pigment also resembles bone corpuscles but lie anterior to retinal vessels; thereby they hide the course of vessels.

## Detachment of Choroid

It is the separation of choroid from sclera.

### Etiology

- It may occur within the first few days following an intraocular surgery as a result of sudden lowering of IOP, for example, trabeculectomy with excessive filtration → sudden lowering of IOP → increased vasodilatation → exudation into outer lamellae of choroid → choroidal detachment.
- Severe choroidal hemorrhage.
- Choroidal tumors.
- Trauma.
- Plastic iridocyclitis (exudation from iris and ciliary body is profuse).

In choroidal detachment, there is no vitreoretinal traction, so photopsia and floaters are absent. Choroidal detachments are limited anteriorly by scleral spur and do not extend to posterior pole because they are limited by firm adhesions between suprachoroidal lamellae, where vortex veins enter their scleral canals.

### Clinical Signs

- Very low IOP.
- Shallow anterior chamber.
- **Ophthalmoscopically**, dark brown mass is seen through pupil.

If IOP remains low and anterior chamber remains shallow for a long period (e.g., in trabeculectomy with excessive filtration), iris remains long in contact with cornea at the angle of anterior chamber and peripheral anterior synechiae may form. Thus, secondary (obstructive) glaucoma may develop.

### Treatment

- Postoperative choroidal detachments resolve by itself.
- In trabeculectomy with excessive filtration, ensure that wound or conjunctival flap is not leaking. If it is, it should be repaired.
- If choroidal detachment is not settled, drainage of suprachoroidal fluid through sclera and reestablishment of anterior chamber with balanced salt solution is done.

## Congenital Anomalies of Uveal Tract

### Heterochromia of Iris (Hetero = Different; Chromia = Color)

Heterochromia is the variation in iris color. Variation in iris color may be in the same iris (when a sector of iris has a different color from the remainder) and the condition is called **heterochromia iridis** (Fig. 9.26), or it may be

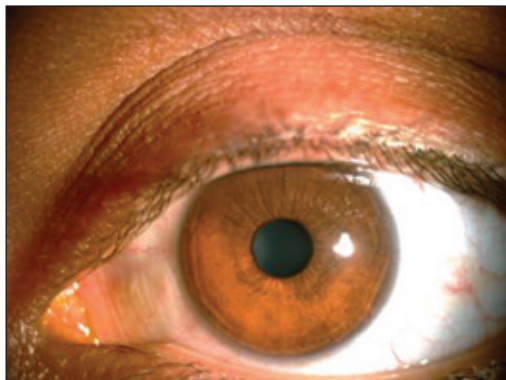


Fig. 9.26 Heterochromia iridis.

between two iris (when one iris has different color from the other) and the condition is called **heterochromia iridium**.

Heterochromia may be congenital or acquired as in Fuch's heterochromic iridocyclitis, siderosis and melanoma of iris.

### Albinism

- It is a hereditary condition with defective development of pigment throughout the body.
- It is divided into:
  - ◇ Ocular.
  - ◇ Oculocutaneous.
  - ◇ Cutaneous forms.

### Clinical Features

Symptoms:

- Absence of pigment in the eye—iris look pink; the patient suffers from glare.
- Nystagmus.
- Photophobia.
- Defective vision.
- Strabismus may be present.

Signs:

- Retinal and choroidal vessels are seen with ophthalmoscope.
- Sclera shines between the vessels.

Types:

- Total albinism: It is extremely rare as traces of pigment have been found in RPE.
- Partial albinism: It is common and the absence of pigment is limited to choroid and retina. The macular regions are pigmented and appears normal.

Treatment:

- Use of tinted glasses to prevent glare.

### Anomalies of Pupil

Normally, pupil is slightly nasal to the center of cornea. If pupil is abnormally eccentric, it is called corectopia. If more than one pupil is present, the condition is called polyopia.

### Aniridia (Irideremia)

It is the absence of iris and is usually bilateral. Usually a narrow rim of iris tissue is present at the ciliary border, but it is hidden behind the sclera. Zonules of lens (suspensory ligaments) and ciliary processes are often visible due to aniridia. Anterior chamber angle anomalies in aniridia lead to development of secondary glaucoma.

### Persistent Pupillary Membrane

It represents the persistence of a part of anterior vascular sheath of the lens; a fetal structure normally disappears before birth. Fine, stellate-shaped spots of pigmented tissue are scattered on the lens surface. These can be distinguished from broken posterior synechiae, as these are stellate in shape and regularly arranged with no signs of iritis.

### Coloboma of Uveal Tract

A coloboma is the absence of a part of an ocular structure as a result of incomplete closure of the embryonic fissure. In the fully developed eye,

**embryonic fissure is inferior and slightly nasal** and extends from the optic nerve to the margin of pupil (anterior part of optic cup). Coloboma may be typical or atypical. Typical coloboma is due to defective closure of embryonic fissure. So, these occur in the **inferonasal** quadrant. It may involve the entire length of fissure (**complete coloboma**), extending from pupil to optic nerve and giving rise to leukocoria, or it may involve only part of fissure, resulting in coloboma of a part (iris, ciliary body, choroid and retina or optic disc). Atypical coloboma is not related with nonclosure of embryonic fissure, so it is found in other positions. Retinal detachment may occur due to break within or outside coloboma.

### Cysts of Iris

*Congenital cysts of iris* arise from stroma or pigment epithelium. *Implantation cyst of iris* occurs after performing ocular injury or intraocular surgery. It has a characteristic pearly appearance. *Serous cysts of iris* are due to closure of iris crypts with retention of fluid.

## Study Questions (MCQs)

**Q1. Which is one of the earliest features of anterior uveitis?**

- A. Keratic precipitates
- B. Hypopyon
- C. Posterior synechiae
- D. Aqueous flare

**Q2. A 27-year-old male presents with redness, pain, and diminution of vision in his right eye for past 5 days. He also gives history of back pain. On examination there are circumcorneal congestion, fine keratic precipitates on corneal endothelium, and 2+ cells in anterior chamber. The intraocular pressure is within normal limits. What is the most likely diagnosis?**

- A. Viral keratitis
- B. Hypertensive iridocyclitis
- C. HLA B-27 associated anterior uveitis
- D. Juvenile chronic arthritis related anterior uveitis

**Q3. Which of the following statements is INCORRECT about phthisis bulbi?**

- A. The intraocular pressure is increased
- B. Nonfunctional eye
- C. Degenerative changes in ciliary body due to chronic recurrent uveitis
- D. Size of the globe is reduced

**Q4. Following are the investigations done for diagnosis of nongranulomatous anterior uveitis EXCEPT**

- A. Erythrocyte sedimentation rate
- B. Rheumatoid factor
- C. Antinuclear antibodies
- D. Quantiferon test

**Q5. Festooned pupil is seen in**

- A. Occlusio pupillae
- B. Anterior synechia
- C. Incomplete posterior synechia
- D. Iris tears

**Q6. What is INCORRECT regarding keratic precipitates?**

- A. Seen in anterior uveitis
- B. Can be pigmented
- C. Deposits on descemets membrane
- D. Comprise of inflammatory cells

**Q7. Granulomatous uveitis is seen in**

- A. Tuberculosis
- B. Behcet's disease
- C. Herpes simplex infection
- D. Multiple sclerosis

**Q8. A patient complains of acute-onset redness and pain in left eye. Circumcorneal congestion, keratic precipitates, anterior chamber reaction, posterior synechiae, and a normal posterior segment points to a diagnosis of**

- A. Acute angle closure glaucoma
- B. Acute iridocyclitis
- C. Acute corneal ulcer
- D. Acute endophthalmitis

**Q9. What is the most common complication of recurrent anterior uveitis?**

- A. Complicated cataract
- B. Secondary glaucoma
- C. Ciliary staphyloma
- D. Vitreous hemorrhage

**Q10. Which of the following is TRUE in Fuchs' heterochromic iridocyclitis?**

- A. Hyphema during cataract surgery is seen
- B. Shows a good response to cycloplegics
- C. Lens implantation following cataract surgery is contraindicated
- D. Development of secondary glaucoma is common complication

**Q11. A 25-year-old female presented with seeing floaters in both the eyes with mild blurring of vision for the last 3 days. On examination best corrected visual acuity in RE is 6/9 and LE is 6/6. Circumciliary congestion in conjunctiva and Keratic precipitates (KPs) is absent. Cells were seen in anterior vitreous. What is the probable diagnosis?**

- A. Fuchs' heterochromic iridocyclitis
- B. Intermediate uveitis
- C. Central focal choroiditis
- D. Endophthalmitis

**Q12. Occlusio pupillae is seen in iridocyclitis. Which of the following is acceptable?**

- A. 360-degree posterior synechiae
- B. Organized exudates blocking the pupil
- C. Forward bulging of whole iris diaphragm
- D. Leaking lens material due to iridocyclitis block the pupil

**Q13. Following topical drugs are the choice for acute iridocyclitis:**

- A. Steroids + Atropine + Acetazolamide
- B. Steroid + Acetazolamide + Antibiotic
- C. Acetazolamide + Atropine + Antibiotic
- D. Steroid + Atropine

**Q14. Hypertensive iridocyclitis is**

- A. Systemic hypertension with anterior uveitis
- B. Rise of intraocular pressure due to posterior uveitis
- C. Rise of intraocular pressure due to anterior uveitis
- D. It is a secondary glaucoma due to development of seclusio pupillae

**Q15. Snow banking is white snowball-like exudates near ora serrata involving pars plana. This a characteristic feature of pars planitis. These lesions can be seen with the following method:**

- A. Under oblique illumination examination
- B. Slit lamp biomicroscopy
- C. Direct ophthalmoscopy
- D. Indirect ophthalmoscopy

## Key

S. No.	Answer
1	D
2	C
3	A
4	D
5	C
6	C
7	A
8	B
9	A
10	A
11	B
12	B
13	D
14	C
15	D