

## CASE REPORT

## Giant Neurofibroma of Sciatic Nerve: Function Preserving Excision

Sandeep Mehrotra<sup>1</sup>, Praveer Ranjan<sup>2</sup>

**Abstract** Peripheral nerve sheath tumors are commonly small and involve superficial nerves. Giant tumors are rare, but usually involve deep nerves. Massive lesions need customized surgery to enable complete excision without sacrifice of residual nerve function. A middle age female presented with a swelling of 2 yrs duration occupying the entire left posterior thigh. CT scan and trucut biopsy were indicative of a massive benign spindle cell tumor arising from the sciatic nerve. This was completely excised by microsurgical dissection safeguarding uninvolved fascicles with no post operative sensory motor deficit. The excised specimen weighed 1950 grams and contained 1300 ml of hemorrhagic fluid within thick walls. Histopathology and Immunohistochemistry confirmed the lesion to be a benign neurofibroma. At 18 months follow up, the patient has no evidence of neurologic deficit or recurrence. Giant neurofibromas are rare, with this case probably the largest reported. Function preserving approach is desirable and possible.

**Keywords:** Giant Neurofibroma, Sciatic nerve

**Key Messages:** Giant neurofibromas are rare, the present report of a 1950gms lesion of the sciatic probably the largest reported. Curative complete excision may be feasible without residual nerve function sacrifice in selected cases.

### Case History

A 46 yr female presented with left posterior thigh swelling of 2 yrs duration. Insidious and painless, the lesion progressed to nearly a foot in dimension and was interfering in her sitting. There were no associated symptoms or co morbidities and no contributory personal or family history.

The 28 x 14 cm solitary, uniformly firm swelling had overlying visible subcutaneous veins (Fig 1a). Mobility across the long axis was not restricted on hamstring contraction with no neurovascular deficit. General, ocular and musculoskeletal examination was normal with no cafe' au-lait spots or dermal neurofibromas.

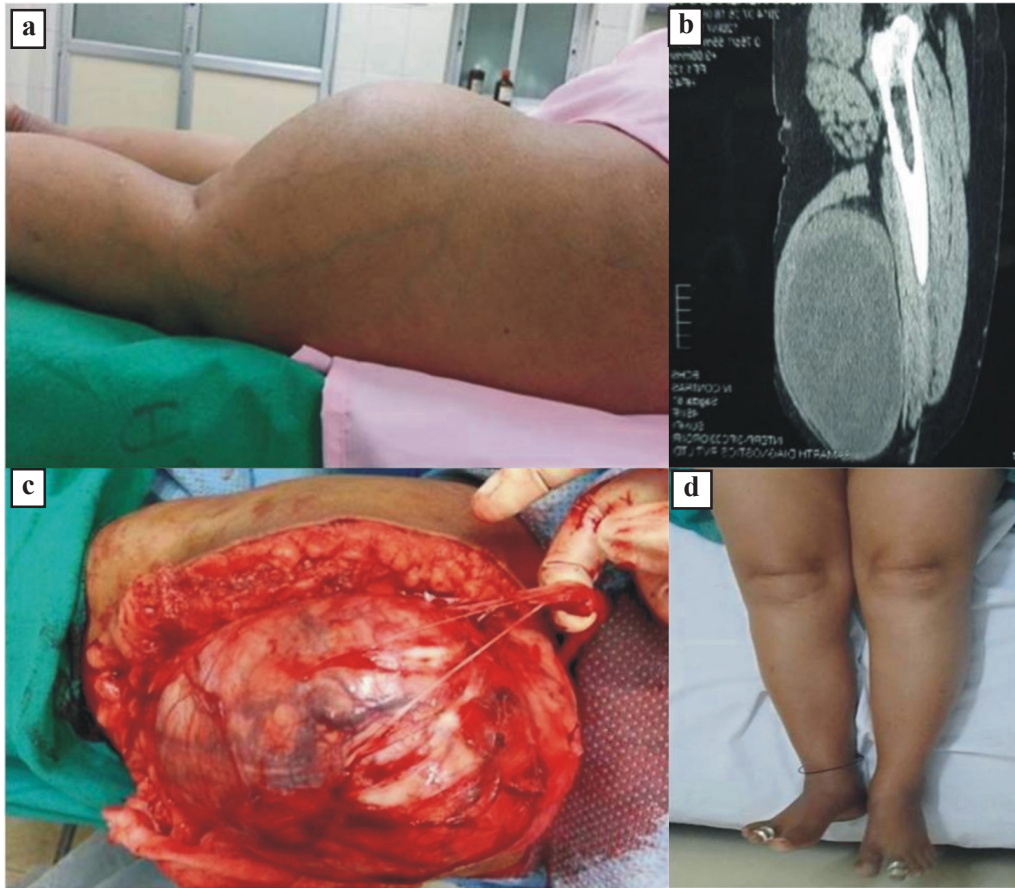Color Doppler revealed a well defined solid cystic lesion with no vascular abnormality. On contrast CT, the lesion, epicentered between the hamstrings, was heterogeneously hypodense with peripheral isodense margin enhancing on contrast. No calcification, fat density or invasion was evident. The sciatic nerve was stretched over the mass while femoropopliteal vessels and femur were normal. (Fig. 1b) Trucut biopsy was reported as benign spindle cell tumor. Hematological and biochemical investigations were normal.

Surgery was done under spinal anesthesia in prone position without tourniquet. The lesion was arising from and encased in the sciatic nerve sheath. Femoropopliteal vessels, proximal sciatic nerve and its tibio peroneal trunks were safeguarded. The sciatic nerve and its divisions, which were stretched thin over the lesion, were microsurgically dissected with preservation of uninvolved fascicles. (Fig 1c) Numerous arterial feeders and draining veins needed ligation during removal. The 1950 gms specimen was bisected and revealed inch thick shaggy walls containing 1300 ml of hemorrhagic fluid. The patient had a smooth post operative recovery with no sensory motor deficit. (Fig 1d) On histopathology, the tumor was composed of bland spindle cells in short fascicles in abundant myxoid stroma. The elongated cells, with moderate eosinophilic cytoplasm showed wavy nuclei with pointed ends and inconspicuous nucleoli. No mitosis, cellular pleomorphism or heterologous differentiation was seen. Immunohistochemistry revealed the lesion to be Vimentin positive; S100 was focally positive in spindle cells while SMA smooth muscle actin (SMA) was negative. The final histopathology diagnosis was of a neurofibroma. (Fig 2 a-d)

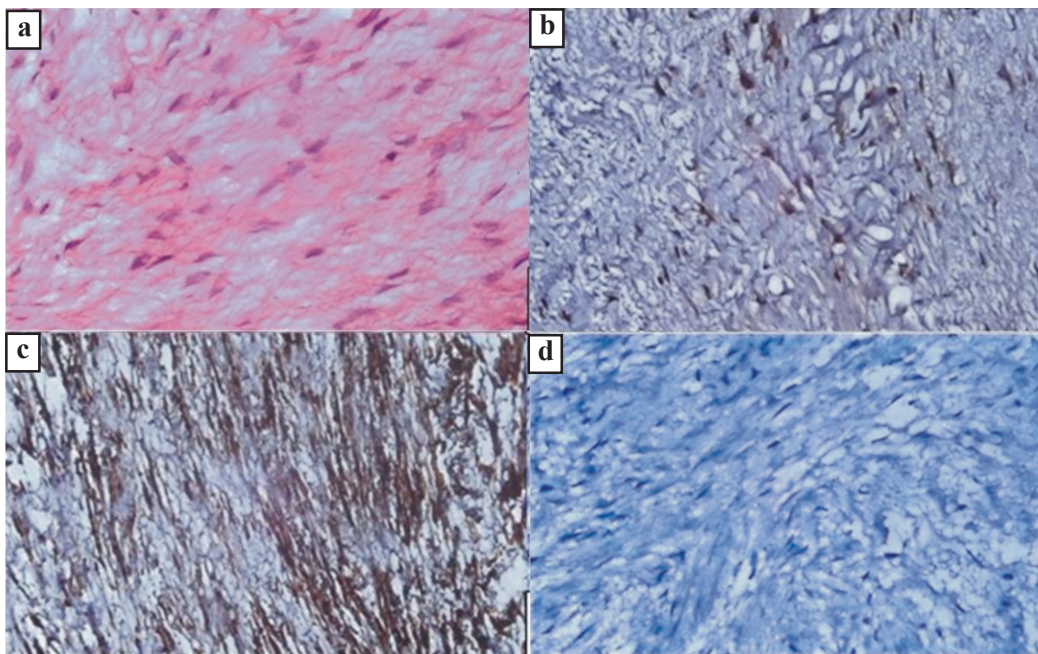
✉ Sandeep Mehrotra  
+91 8407984852  
smehrotra21@gmail.com

<sup>1</sup> Professor, Plastic & Reconstructive Surgery  
Army Hospital (Research & Referral), New Delhi- 110010

<sup>2</sup> Senior Advisor, Dept of Pathology  
Command Hospital (Southern Command)  
Pune- 411040, India



**Fig. 1** (a) Massive soft tissue swelling lt thigh. (b) CT scan: Well defined central hypodense mass with peripheral isodense margin. No calcification or fat density. (c) Tumor arising from sciatic nerve. Excision with preservation of tibio peroneal trunks. (d) Normal foot dorsiflexion post operatively.



**Fig. 2** (a) Photomicrograph showing pattern less arrangement of spindle cells in myxoid background. Scattered nuclei are thin and wavy (Hematoxylin and eosin stain x200). (b) Immunohistochemistry showing scattered S-100 positive cells (IHC: S100 protein x100). (c) Intervening cells positive for Vimentin (IHC: Vimentin x100). (d) Cells uniformly negative for Calretinin (IHC: Calretinin x100)

## Discussion

Neurofibromas are benign nerve sheath tumours, described by Smith in 1849 and later by von Recklinghausen in 1882<sup>1</sup>. The majority are solitary and small, with even distribution over body surface dermis or subcutis<sup>2,3</sup>. Rarer deep lesions are usually axial, involve important motor / mixed nerves and their excision is associated with significant morbidity<sup>3</sup>. Giant neurofibroma of the sciatic nerve is rare, with few reports. Our case is probably the largest neurofibroma reported in published literature till date. Arising from the left sciatic nerve, it was successfully excised microsurgically, while preserving nerve function. The patient remains recurrence free on 18 months follow up.

Neurofibromatosis is a generic denomination for three multisystem autosomal dominant genetic diseases: neurofibromatosis type I (NF1, commonly peripheral), neurofibromatosis type 2 (NF2, central nervous system), and schwannomatosis. We could not identify any generic criteria for neurofibromatosis types in our patient. Neurofibromas are histologically divided into: i) Nodular neurofibromas arising from perineural cells which can be removed without significant nerve damage and ii) plexiform neurofibromas with perineural cell involvement and invariable neurologic deficit following surgical extirpation.

Neurofibromas commonly present as cutaneous nodes (localized cutaneous neurofibroma) and rarely as self contained masses in peripheral nerves (localized intraneural neurofibroma) or as diffuse growths of larger nerve branches or of several adjacent nerves (plexiform neurofibroma). Our case conforms to the localized intraneural type. Most are well circumscribed, between 1 and 2 cm and typically white-grey, though they may be polypoid or fusiform in shape<sup>4</sup>.

Histologically neurofibromas contain interlacing bundles of elongated closely arranged cells with wavy, dark staining nuclei, slender cytoplasmic processes and minimal mucoid material<sup>5</sup>. Neurofibromas lack epithelial elements, demonstrate S-100 positivity, typically in some but not all of their component spindle cells. In keeping with their benign behaviour they lack significant mitotic activity. The histomorphology features of the tumor we excised conformed to these typical features.

NF1 often affects soft tissue with tumor growth and expansion causing increased morbidity. Surgical management is the most effective method to control or cure this tumor. Rarely, some neurofibromas may turn malignant, metastasize early and carry a poor prognosis<sup>6,7</sup>. Though massive in size, there were no clinical, radiologic, surgical or pathologic features of malignancy in our case.

Schwannomas and neurofibromas, both involve the sciatic nerve only rarely. In neurofibromas fascicular bundles are more intimately involved, unlike schwannomas, making dissection difficult<sup>8</sup>. In our case, with magnification, it was possible to dissect and safeguard the normal fascicles while sacrificing only the involved ones. An english literature search for similar cases revealed one report of a 155gm tumor which was excised with no complication<sup>9</sup>. In our case, the neurofibroma was solitary with no cafe' au lait spots or other features suggestive of NF1. The tumor was massive (1950 gms), well encapsulated and clearly arising from a few fascicles of the sciatic nerve. The major portion of the weight and size was contributed to by the 1300 ml hemorrhagic fluid. Arterial dysplasia and vascular fragility is reported in rare cases of NF1 associated bleeding<sup>8</sup>. This may explain the intratumoral bleed, but our patient did not report a sudden increase in size of the lesion at any time.

This is possibly, at 1950 grams, the largest reported sciatic nerve neurofibroma which was removed with preservation of neurological function. At 18 months follow up, there is no evidence of recurrence or residual disease.

## References

1. Sherman JE, Smith JW: Neurofibromas of the breast and nipple areolar area. *Ann Plast Surg* 1981, 7:302-307
2. Benign tumors of peripheral nerves. In Enzinger and Weiss's Soft Tissue Tumours 4th edition. Edited by: Weiss SW, Goldblum JR. St. Louis: Mosby; 2001:1111-1208.
3. Fletcher CDM: Peripheral neuroectodermal tumours. In *Diagnostic Histopathology of Tumours* 2nd edition. Edited by: Fletcher CDM. Edinburgh: Churchill Livingstone; 2000:1679-1711.
4. Neurofibroma. In *Diagnostic Pathology of Nervous System Tumours* Edited by: Ironside JW, Moss TH, Louis DN, Lowe JS, Weller RO. London: Churchill Livingstone; 2002:439-444.
5. Benign tumors of peripheral nerves. In Enzinger and Weiss's Soft Tissue Tumours 4th edition. Edited by: Weiss SW, Goldblum JR. St. Louis: Mosby; 2001:1111-1208
6. Vauthey JM, Woodruff JM, Brennan MF. Extremity malignant peripheral nerve sheath tumors (neurogenic sarcomas): a 10yr experience. *Ann Surg Oncol* 1995;2:126.
7. Wong WW et al. Malignant peripheral sheath tumors: analysis of treatment outcome. *Int J Oncol Biol Phys* 1998; 42: 351.
8. Wolkenstein P, Mitrofanoff M, et al. Bleeding: A Complication of Neurofibromatosis I Tumors. *Arch Dermatol*. 2001;137:233-234. Wazir MA, Wazir U. Massive neurofibroma of the sciatic nerve. *JPMI*. 2003; 17:273-275.
9. Wazir MA, Wazir U. Massive neurofibroma of the sciatic nerve. *JPMI*. 2003; 17:273-275.