

# Nerve Transfers to Restore Shoulder and Elbow Functions in Upper Brachial Plexus (C5-C6) Injury—A Technical Note

Dattaraj Sawarkar<sup>1</sup> Sumit Sinha<sup>2</sup>

<sup>1</sup>Department of Neurosurgery and Gamma Knife Center, All India Institute of Medical Sciences, New Delhi, India

<sup>2</sup>Department of Neurosurgery, Paras Hospital, Haryana, India

**Address for correspondence** Sumit Sinha, MS, MCh, Department of Neurosurgery, Paras Hospital, C-1, Sushant Lok, Phase 1, Gurugram, Haryana, India (e-mail: dattaraja@gmail.com).

J Peripher Nerve Surg:2020;4:30–37

## Abstract

Brachial plexus injury is very commonly associated with road traffic accidents, especially motorcycle accidents, and frequently affects young adults, causing significant disability and impact on quality of life. These are devastating injuries leading to socio-economic loss of not only the individual but also of the society and account for 10–20% of traumatic peripheral nerve injuries. In the past decade, nerve transfers have become the mainstay of the treatment in upper brachial plexus injuries. Brachial plexus surgeon has many options in his armamentarium to have increased functional outcome and his / her choices are dependent upon evaluation of the overall severity of the injury, available literature and personal experience and expertise with various surgical techniques. The priorities in the adult brachial plexus injury reconstruction are return of elbow function followed by shoulder recovery and stabilization. C5.6 injuries have a better prognosis with chances of recovery of shoulder and elbow function in the range of 85–90%, using these distal transfers, which have revolutionized the field of brachial plexus surgery.

## Keywords

- brachial plexus injury
- surgery
- nerve transfer
- outcome

## Introduction

Brachial plexus injury is very commonly associated with road traffic accidents, especially motorcycle accidents, and frequently affects young adults, causing significant disability and impact on quality of life.<sup>1,2</sup> These are devastating injuries leading to socioeconomic loss of not only the individual but also of the society. Brachial plexus injuries account for 10 to 20% of traumatic peripheral nerve injuries causing motor and sensory loss to the upper limb.<sup>3</sup>

Historically, the repair strategies have consisted of brachial plexus exploration and reconstruction with nerve grafting.<sup>4</sup> During the early twentieth century, results were so disappointing that it led to therapeutic nihilism to the extent that either conservative or amputation was advised as the treatment of choice. However, after the pioneering work of Herbert Seddon during World War II, and later, improved

results shown by Narakas, Gilbert, Tassim, Kawabata, and Millesi resulted in generation of new interest in this field.<sup>5</sup>

Nerve transfers with extraplexal donors were already introduced in the early 20th century, but in 1990, French surgeon, Christophe Oberlin completely revolutionized the treatment by his new idea of co-opting motor fibers from ulnar nerve to nerve fascicle (nerve to biceps) of musculocutaneous nerve (MCN), resulting in better functional outcomes.<sup>6</sup> This approach sacrifices a functional donor nerve fascicle in an attempt to reinnervate a recipient denervated target muscle. In fact, many surgeons now choose to forgo brachial plexus exploration and rely solely on distal nerve transfers.<sup>4</sup>

Various surgical techniques, such as tendon transfers, nerve grafts, and nerve transfers, can restore some motor functions. The proximal nerve transfers are traditional strategies

that include nerve grafts between the divided nerve roots or trunks of the brachial plexus and the distal nerve stumps.<sup>7</sup> In a distal nerve transfer, an intact nerve can be selected for coaptation to the distal stump of the injured nerve as a method of reinnervating a critical sensory or motor unit.<sup>7</sup>

Nerve transfer, or neurotization, in which a donor nerve is sacrificed and sutured to the distal end of the recipient nerve, produces better functional outcomes, minimizes reinnervation time, has few co-contraction problems, and prevents disruption of the tendon-muscle unit balance.<sup>8</sup> Direct neurotization or nerve grafting close to the target motor endplate can successfully restore peripheral nerve function.<sup>8</sup>

Upper plexus injury can cause loss of elbow flexion, shoulder abduction, and shoulder joint instability (C5-C6 injury) or loss of elbow extension (C5, C6, C7 injury) causing inability to perform activities of daily living. Restoration of elbow flexion has major role of injury treatment, and is the first choice of nerve transfers,<sup>2,9,10</sup> which is followed by nerve transfers to stabilize shoulder joint.<sup>2</sup>

The aim of this article is to discuss in detail the nerve transfers commonly used for the treatment of upper brachial plexus (C5-C6) injuries.

## General Principles of Nerve Transfers

The axonal regeneration progresses at a rate of 1 to 2 mm/day.<sup>11</sup> Because muscle fibers undergo irreversible changes after 12 to 18 months of denervation,<sup>12</sup> it is imperative that treatment be undertaken promptly for functional recovery.

The primary aim of nerve transfers is to promote reinnervation in proximity to a certain target organ (whether a muscle or a skin territory) following a proximal nerve injury.<sup>13</sup> Transferring a motor nerve that is close to the motor endplate shortens the distance for axon regeneration and consequently the time for muscle reinnervation. In this respect, nerve transfer promotes a functional rather than an anatomical reconstruction. This is the main concept in nerve transfer surgery. Furthermore, the direct anastomoses is better, rather than using a nerve graft, as it increases reinnervation time and ultimately leads to poor outcomes. On an average, approximately 30% of axons are lost at the time of crossing each anastomotic line.

A thorough selection of donor and recipient nerves requires a clear understanding of nerve transfer principles. The health of donor nerve is an important determining factor for the success of the nerve transfer. A careful assessment of functioning and nonfunctioning musculotendinous units in the extremity should be performed to determine which nerves are available for transfer. The available nerve should be a functional normal nerve and expandable, which can sustain the loss of portion of its axons with minimal loss of function.<sup>14,15</sup>

The synchronicity of donor and recipient nerve function is preferable although not always necessary, because reeducation is easy for functional recovery,<sup>16</sup> and there are no concerns for cortical plasticity.

The donor nerve should be mobilized and cut as distally as possible and recipient nerve should be cut as far proximally

**Table 1** Various nerve transfers used to restore shoulder and biceps function

Donor nerve	Recipient nerve
Spinal accessory nerve	Suprascapular nerve (MC)/Axillary nerve / Musculocutaneous nerve
Phrenic nerve	Suprascapular nerve (MC)/ Musculocutaneous nerve
Intercostal nerve	Musculocutaneous nerve/ Axillary nerve
Subscapular nerve	Musculocutaneous nerve/ Axillary nerve
Thoracodorsal nerve	Musculocutaneous nerve/ Axillary nerve
Pectoral nerve	Musculocutaneous nerve/ Axillary nerve
Oberlin's transfer (partial ulnar and radial nerve)	Musculocutaneous nerve
Somsak's transfer (partial radial nerve)	Axillary nerve

Abbreviation: MC, musculocutaneous.

to have direct tension-free anastomosis without postural compensation.<sup>17</sup>

The donor nerve should have adequate number of donor axons and it is recommended that the number of nerve fibers in donor axons should be at least more than 30% of the number of nerve fibers in the recipient nerve.<sup>16,18</sup> Various nerve transfers used to restore shoulder and biceps function are given in ► **Table 1**.

## Strategy for C5-C6 Avulsion Injuries

The injury to upper trunk (C5-C6) of the brachial plexus results in the loss of elbow flexion as well as shoulder abduction/external rotation.

### Nerve Transfers for Shoulder

#### Spinal Accessory Nerve to Suprascapular Nerve Transfer

The spinal accessory nerve (SAN) is the cranial nerve that supplies sternocleidomastoid and trapezius muscles. This nerve has approximately 1,500 to 1,700 nerve fibers. The transfer of SAN is one of the most common nerve transfer procedures.<sup>19</sup> The use of SAN for neurotization was first described in the early twentieth century but was largely popularized in the 1960s by Kotani et al.<sup>20</sup>

The SAN to suprascapular nerve (SSN) transfer is commonly used in upper brachial plexus injury to achieve stabilization of shoulder in space and restore shoulder function, especially, initiating the first 30 degrees of shoulder abduction. This transfer provides satisfactory restoration of shoulder function.<sup>19,21,22</sup> In pan-plexal injuries, SAN is also used by some authors via an interposition graft, for neurotizing axillary nerve (for shoulder function) or MCN (for elbow flexion).<sup>19,21,22</sup>

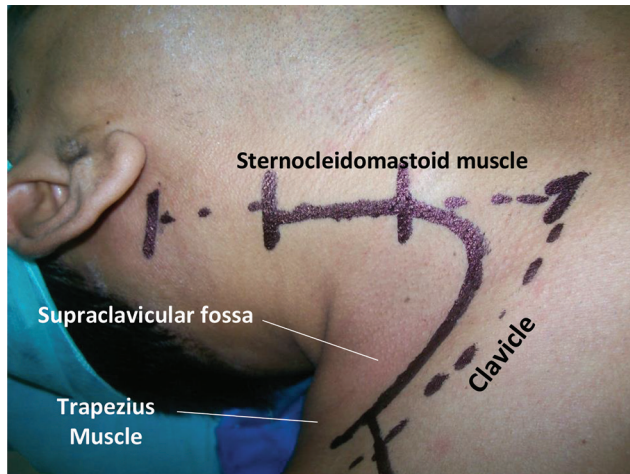
The SAN travels underneath the superficial and mid-cervical fascia in the supraclavicular fossa, after innervating the sternocleidomastoid muscle (SCM). It crosses distally over

the terminal rami of the transverse cervical vessels, passes under the superficial rami of cervical plexus, and gives motor branches to upper trapezius around 3 cm above the clavicle. SAN can be exposed via both the ventral or dorsal approach, which is heavily debated by the proponent of both approaches. The arguments in favor of dorsal approaches cite more favorable results due to appropriate decompression of nerve at scapular notch and its cooptation with the donor nerve in close proximity to muscle target.

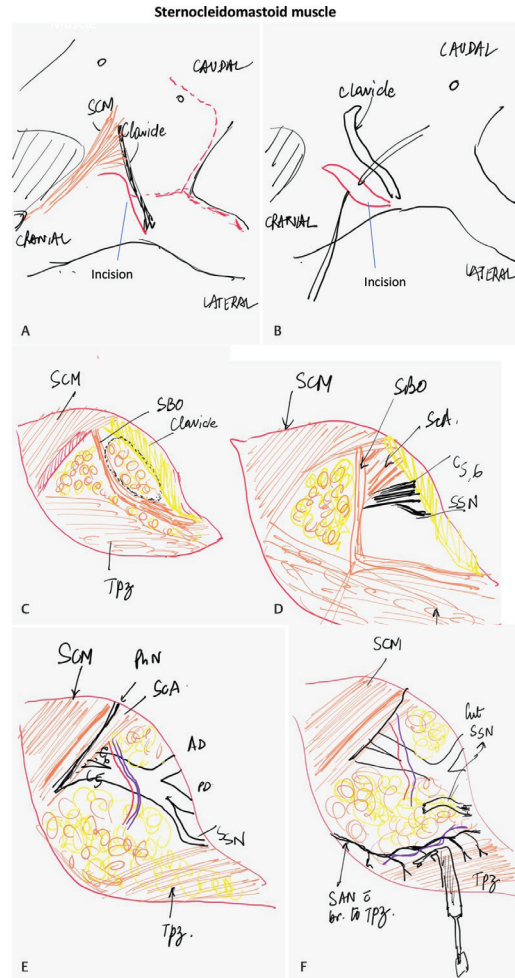
**Technique—Ventral Approach**

The SSN arises from the upper trunk of brachial plexus, and runs laterally beneath the omohyoid muscle toward the suprascapular notch. The omohyoid muscle can be used as a surgical landmark to find the nerve. The skin incision is placed 2 cm above and parallel to the clavicle starting slightly medial to lateral border of SCM for around length of 4 to 5 cm (→ Fig. 1). The platysma muscle is dissected separately and cut exposing the lateral border of SCM muscle which is then lifted up to expose fat body present in the supraclavicular fossa. The supraclavicular fat pad is then mobilized in lateral direction, leaving it pedicled rather than excising it. This dissection opens up the supraclavicular space, visualizing the upper trunk, which when followed distally and laterally identifies the SSN. Another important landmark is the omohyoid muscle, which arises in between SCM and scalenus anticus muscle and crosses laterally over the upper trunk. The SSN can be identified following omohyoid muscle laterally, which follows lateral to the acromial trajectory. The SSN is then dissected as far as possible through the fatty supraclavicular layer and cut proximally just after its origin from the upper trunk (→ Figs. 2A–F and 3).

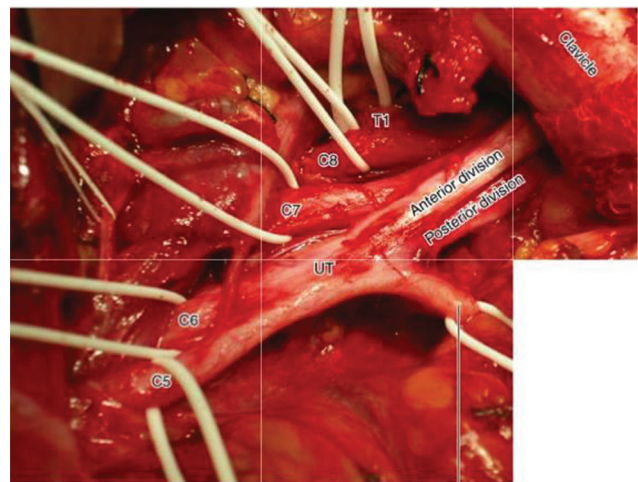
During the ventral approach, the SAN is identified on the anterior surface of the trapezius muscle with the help of intraoperative stimulation and it is then dissected as far distally as possible to have adequate length for a tension-free



**Fig. 1** Incision for supraclavicular exploration for the spinal accessory to suprascapular nerve transfer.



**Fig. 2 (A–F)** Supraclavicular exploration of brachial plexus. Abbreviations: AD, anterior division; PD, posterior division; PhN, phrenic nerve; SAN, spinal accessory nerve; SBO, superior belly of omohyoid; SCA, subclavian artery; SCM, sternocleidomastoid muscle; SSN, suprascapular nerve; Tpz, trapezius muscle.



**Fig. 3** Intraoperative photograph of supraclavicular exposure.



anastomosis. During the dissection of SAN, great care is taken to preserve 3 to 4 twigs of SAN to the trapezius muscle to save trapezius function (►Fig. 2F). Under microscopic magnification, an end-to-end microanastomosis is performed with 10-0 nylon and it is then reinforced with tissue glue.

SAN to SSN transfer provides a satisfactory restoration of shoulder function. In upper plexal injuries, various authors have achieved a valid shoulder abduction in 90% and favorable external rotation in 30% cases.<sup>19,21,22</sup>

#### Technique—Dorsal Approach

In dorsal approach, the SSN is exposed in the suprascapular notch and tension-free SSN to SAN anastomosis is performed. This is another distal nerve transfer and many authors prefer this over the ventral approach, especially in late cases, as here the anastomosis is performed near to the muscle endplate. This approach requires a clear understanding of the anatomy of this region. The patient is positioned in lateral position. The surface marking of the SAN and SSN is made before the start of the procedure. A line is drawn over the scapular spine. SSN is marked laterally at roughly one-third of the distance between medial border of the scapula and acromion process. SAN is marked medially, about three-fourths of the distance between midline and acromion (►Fig. 4).

The skin incision is given over the spine of scapula from acromion to medial border of the scapula. The attachment of trapezius muscle over scapular spine is cut and plane developed between the supraspinatus and trapezius muscles (►Fig. 5). Next, the dissection is directed laterally toward the suprascapular notch which is then palpated with the index finger. The suprascapular vessels are seen crossing above the shiny white suprascapular ligament, which are then held in a vessel loop. The suprascapular ligament is then cut and SSN is located beneath it (►Fig. 5A, 5B). The SSN is traced proximally and cut with adequate length to ensure a tension-free anastomosis with SAN (►Fig. 5C).

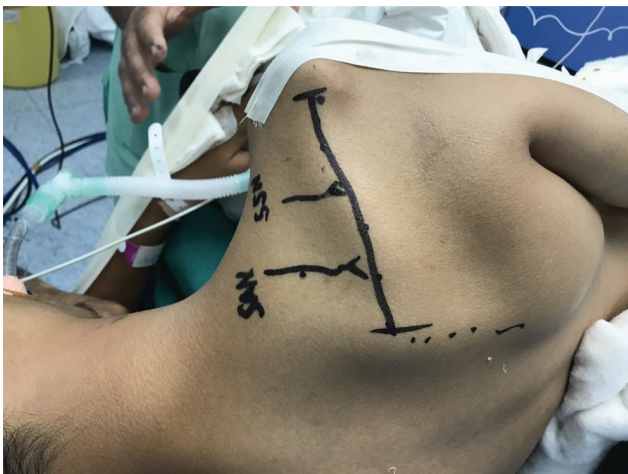


Fig. 4 Surface marking of suprascapular nerve and spinal accessory nerve in dorsal approach.

The SAN is identified running over the undersurface of the trapezius muscle from above downwards medially, passing twigs to the muscle on the way (►Fig. 5D-F). SAN is then cut as distally as possible preserving few branches to trapezius muscle, and anastomosed with SSN with a 10-0 nylon suture (►Fig. 5G).

#### Somsak's Procedure

The injuries to the upper trunk (C5-C6) of brachial plexus result in the loss of shoulder abduction and external rotation as well as elbow flexion. The restoration of shoulder abduction and external rotation is the primary goal in reconstruction of the upper extremity function, after elbow flexion.

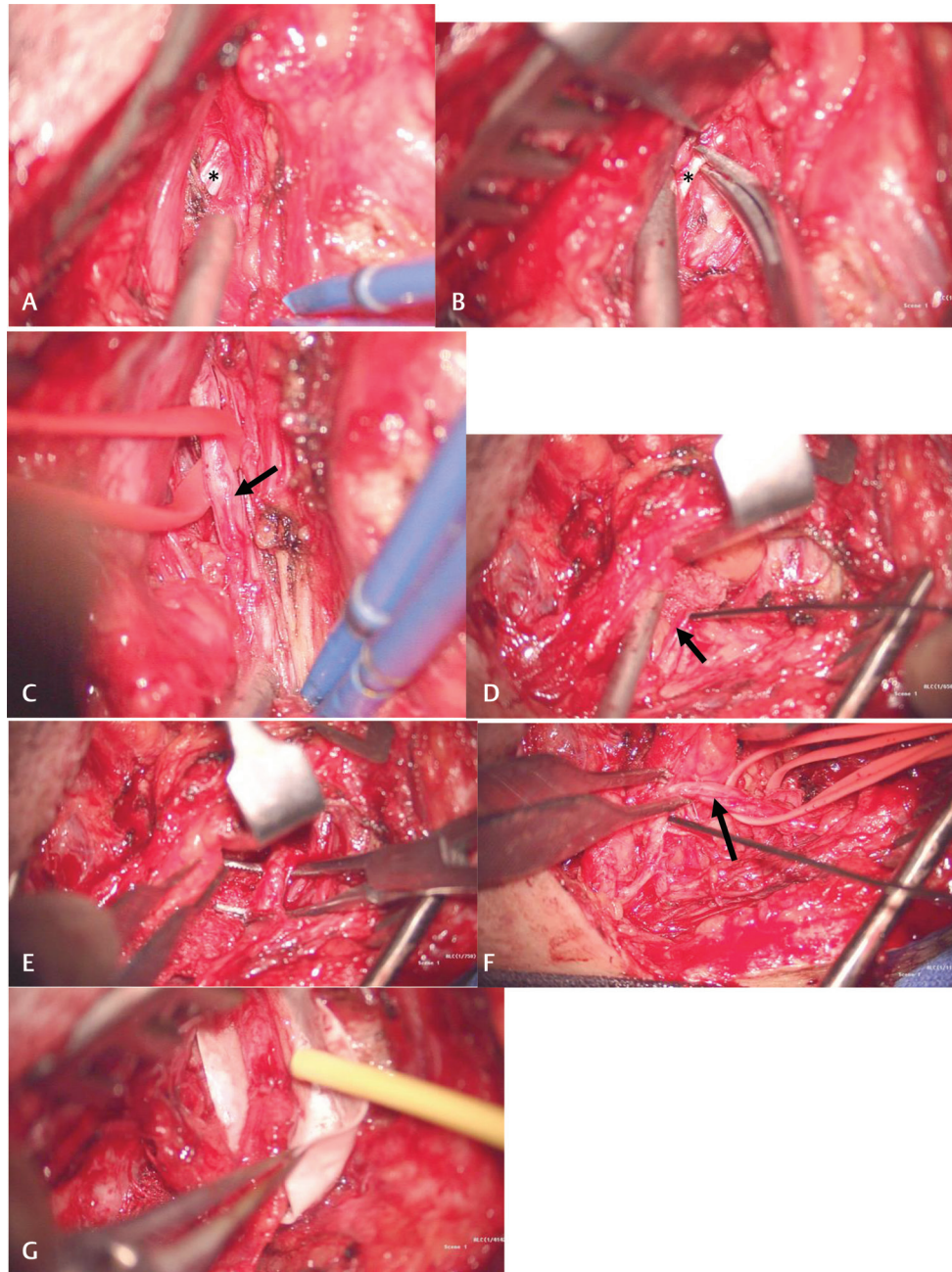
In 2003, Leechavengvongs et al<sup>23</sup> described a novel nerve transfer of a triceps branch of the radial nerve to the axillary nerve to restore shoulder abduction. This procedure has become a preferred reconstruction technique in patients with C5-C6 root avulsions with loss of deltoid function.

This procedure is indicated in upper trunk injury (C5-C6) where there is deltoid palsy causing loss of shoulder abduction. The preservation of triceps function (radial nerve) is mandatory for this procedure, to be able to transfer branch of radial nerve to axillary nerve.

#### Technique

The technique requires a posterior approach via longitudinal incision in quadrilateral space that can be exposed elevating deltoid superiorly. The patient is positioned supine with the affected hand supported in the flag holding position in front of the patient's face. The skin incision runs from the acromion process to the junction of the upper and middle thirds of the arm, between the long and lateral heads of triceps (►Fig. 6A). A plane is developed between these two muscles and the radial nerve between long head and lateral head of triceps is identified in the triangular space (►Fig. 6K), bounded by humerus medially, long head of triceps laterally and teres major muscle superiorly, and its branches are identified using direct nerve stimulation. The branch selected for the transfer is the one for the long head due to its larger number of axons and its proximity with the axillary nerve. The main axillary nerve is identified in quadrilateral space, bounded by teres minor muscle superiorly, long head of triceps laterally, deltoid, humerus and lateral head of triceps medially, and teres major muscle inferiorly (►Fig. 6D). The donor nerve is then coopted with the main axillary nerve or with the anterior branch of axillary nerve (►Fig. 6L). Generally, this procedure is performed via posterior approach but few authors also perform this procedure through anterior approach. Few authors use medial triceps branch rather than long head of triceps branch, as long head of triceps branch not only extend elbow but also provide shoulder stability by adduction and retroversion.<sup>24</sup>

The transfer of triceps branch of the radial nerve to the axillary nerve restore deltoid function in almost all the cases.<sup>23,25</sup>



**Fig. 5 (A–G)** Dorsal approach to SAN-SSN transfer; (A) suprascapular vessels passing superficial to shiny white suprascapular ligament (\*); (B) cutting the ligament (\*) to visualize suprascapular nerve (SSN) passing below; (C) identifying SSN (black arrow) and taking in the vessel loop; (D) identifying distal spinal accessory nerve (SAN) (black arrow) over the surface of trapezius muscle, by intraoperative stimulation; (E, F) tracing the SAN proximally over the trapezius muscle; (G) completed SSN-SAN anastomosis.

Triceps transfer is typically combined with concomitant SAN transfer to the SSN (double transfer); a procedure that can be performed from an anterior or posterior approach.

The triceps branch nerve transfer is a relatively quick and straightforward operation with dissection outside the zone of injury, requires no nerve graft and associated donor-site morbidity, and in theory has quicker deltoid muscle reinnervation with a high success rate.

#### Phrenic Nerve to SSN Transfer

Gu et al popularized the use of phrenic nerve as a donor nerve and many authors reported the usefulness of phrenic

nerve to SSN transfer for shoulder abduction in upper brachial plexus injury.<sup>26-30</sup>

Many authors have considered phrenic nerve as a better donor nerve than the SAN due to the fact that in the phrenic nerve the deficit created by denervating a part of the trapezius muscle, which is one of the scapulothoracic muscles, can be avoided.<sup>30</sup> However, SAN is the preferred donor due to its large number of motor axons and concerns for respiratory compromise with phrenic nerve, especially in infants and smokers.

Phrenic nerve is a pure motor nerve and meets all the criteria of a powerful axon donor. It has around 800 to 1,800



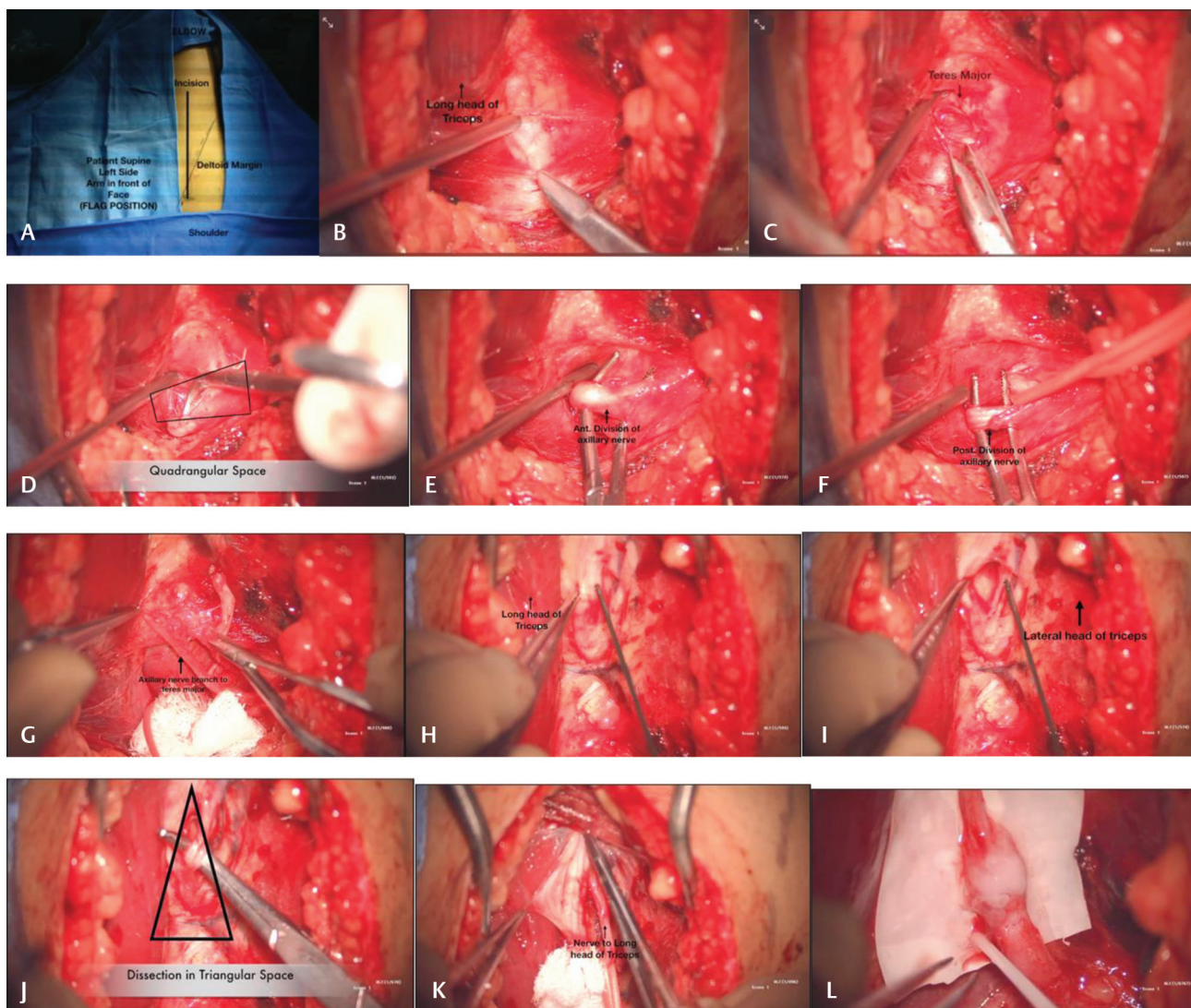


Fig. 6 (A-L) Somsak transfer.

myelinated nerve fibers. Eighty percent patients can achieve 80% or higher Medical Research Council grades. Generally, it does not lead to respiratory problems, but it is not desirable in infants and in patients with chronic pulmonary disease or traumatic pulmonary sequelae.<sup>29,30</sup>

Phrenic nerve has a variable origin from C3 to C5. Sometimes, an accessory phrenic nerve is also present originating either from C3-C4 or C5-C6 which joins the main trunk distal to clavicular level.<sup>19</sup> After its origin, the phrenic nerve runs obliquely in front on the anterior surface of anterior scalenus, passes in front of the subclavian artery, and behind the vein heading toward hemidiaphragm.<sup>19</sup> The phrenic nerve is usually harvested supraclavicularly but Xu et al performed the full-length harvest of the phrenic nerve by means of video-assisted thoracic surgery, which is preferable when surgery is undertaken > 9 months after injury.<sup>31</sup>

The supraclavicular exposure is performed as is done for the SAN to SSN transfer. The phrenic nerve is identified by following the C5 and C6 roots proximally. It crosses these roots and travels lateromedially over the scalenus anticus muscle. The nerve is then confirmed by nerve stimulator.

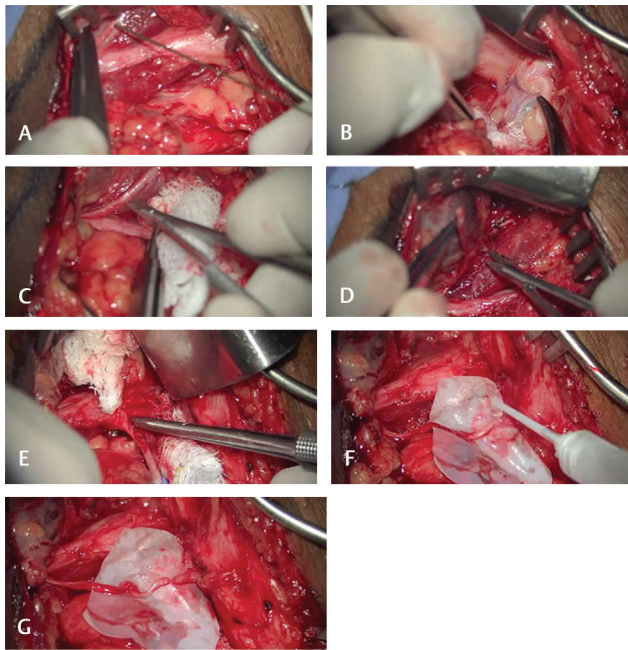
The phrenic nerve is then dissected as distally as possible and cut. The SSN is then identified at the upper border of the upper trunk, being the first branch of the upper trunk. Under microscope guidance, the phrenic nerve was sutured directly without tension to the SSN using interrupted 10-0 nylon stitches placed in the epineurium (► Fig. 7A-G).

### Nerve Transfers for Elbow

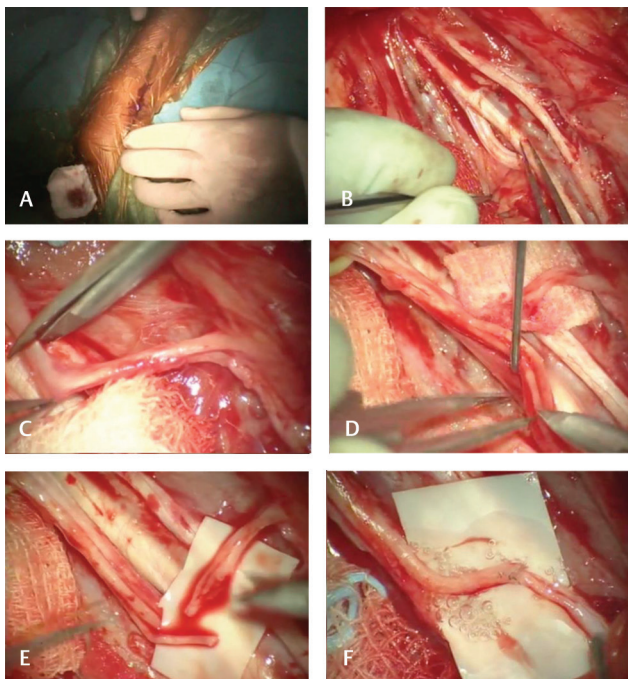
#### Oberlin's Transfer

Christophe Oberlin revolutionized the treatment of brachial plexus injury with description of his novel technique in 1994, which was designed to restore elbow flexion with good functional results. The method is based on biceps muscle reinnervation from flexor carpi ulnaris (FCU) motor fascicle of ulnar nerve.<sup>2,6</sup> Oberlin modified his technique in 2004 to transfer a median nerve fascicle to brachialis motor branch (Oberlin II).

Another popular variant of the classical Oberlin transfer was the transfer of one or two fascicles for wrist flexors in the medial cord (after the take-off of the ulnar nerve) to the whole MCN.<sup>32</sup>



**Fig. 7 (A-G)** Phrenic to suprascapular nerve (SSN) transfer.



**Fig. 8 (A-F)** Ulnar nerve to biceps branch of musculocutaneous nerve transfer (Oberlin's transfer).

This procedure results in an excellent elbow flexion recovery in > 90% of cases, with minimal deficits in the ulnar nerve distribution for patients with C5-C6 or even C5-C7 plexus injuries.<sup>33-35</sup>

#### Technique

The patient lies in supine position with arm abducted at 90 degrees. A linear skin incision is made along the medial surface of the upper arm in the groove between the biceps and triceps muscles (►Fig. 8A). The biceps muscle is then

gently retracted and the neurovascular bundle is identified in the groove between the biceps and triceps muscles. This dissection is then exposed down to distal third of the arm. The MCN is then dissected until the entry point into biceps muscle. The MCN gives rise to 6 to 7 nerves to biceps in total and the one in the mid arm is dissected off from the MCN, and cut as proximally as possible, after checking that it is nonfunctional using intraoperative stimulation. Thereafter, further dissection is undertaken to identify the ulnar nerve which lies more posteriorly, between the biceps and brachialis muscles. The median and ulnar nerves are then traced distally and identified by using a nerve stimulator to provide visual confirmation of appropriate movements. It is preferable to harvest a fascicle for the FCU from the ulnar nerve and flexor carpi radialis from the median nerve. Some authors also use median nerve fascicles innervating flexor digitorum superficialis or palmaris longus. The knowledge of exact topographical anatomy of median and ulnar nerve fascicles is of paramount importance to the surgeon during this surgery. The ulnar nerve is intraneurally dissected and a FCU fascicle is transferred onto the chosen nerve to biceps fascicle. Similarly, the selected fascicle in the median nerve is transferred to brachialis for double nerve transfer (►Fig. 8A-F).

#### Conclusion

In the past decade, nerve transfers have become the mainstay of treatment in upper brachial plexus injuries. Brachial plexus surgeon has many options in his armamentarium to have increased functional outcome and his/her choices are dependent upon evaluation of the overall severity of the injury, available literature, and personal experience and expertise with various surgical techniques. The priorities in the adult brachial plexus injury reconstruction are return of elbow function followed by shoulder recovery and stabilization. C5-C6 injuries have a better prognosis with chances of recovery of shoulder and elbow function in the range of 85 to 90%, using these distal transfers, which have revolutionized the field of brachial plexus surgery. In these partial injuries, phrenic nerve or SAN can be used as good neurotizers for the SSN; however, the latter is more preferred. The deltoid can be additionally neurotized using Somsak transfer (double transfer). These shoulder transfers are combined with Oberlin transfer I or II (triple transfer), for the recovery of elbow.

#### Conflict of Interest

None declared.

#### References

- 1 Thatte MR, Babhulkar S, Hiremath A. Brachial plexus injury in adults: diagnosis and surgical treatment strategies. *Ann Indian Acad Neurol* 2013;16(1):26-33
- 2 Verdins K, Kapickis M. Oberlin's transfer: long term outcomes. *J Hand Surg Asian Pac Vol* 2018;23(2):176-180
- 3 Mumenthaler M. Some clinical aspects of peripheral nerve lesions. *Eur Neurol* 1969;2(5):257-268
- 4 Ali ZS, Heuer GG, Faught RW, et al. Upper brachial plexus injury in adults: comparative effectiveness of different repair techniques. *J Neurosurg* 2015;122(1):195-201



- 5 Sinha S, Sharma R, Khani M, Mansoori N, Adult brachial plexus injuries: surgical strategies. In: Mahapatra AK, Midha R, Sinha S, eds. *Surgery of Brachial Plexus 2016*. 1 st ed. Delhi: Thieme Publisher; India:85–100
- 6 Oberlin C, Béal D, Leechavengvongs S, Salon A, Dauge MC, Sarcy JJ. Nerve transfer to biceps muscle using a part of ulnar nerve for C5-C6 avulsion of the brachial plexus: anatomical study and report of four cases. *J Hand Surg Am* 1994;19(2):232–237
- 7 Doi K. Distal nerve transfer: perspective of reconstructive microsurgery. *J Reconstr Microsurg* 2018;34(9):675–677
- 8 Giuffre JL, Bishop AT, Spinner RJ, Shin AY. The best of tendon and nerve transfers in the upper extremity. *Plast Reconstr Surg* 2015;135(3):617e–630e
- 9 Gutowski KA, Orenstein HH. Restoration of elbow flexion after brachial plexus injury: the role of nerve and muscle transfers. *Plast Reconstr Surg* 2000;106(6):1348–1357, quiz 1358, discussion 1359
- 10 Terzis JK, Vekris MD, Soucacos PN. Outcomes of brachial plexus reconstruction in 204 patients with devastating paralysis. *Plast Reconstr Surg* 1999;104(5):1221–1240
- 11 Pfister BJ, Gordon T, Loverde JR, Kochar AS, Mackinnon SE, Cullen DK. Biomedical engineering strategies for peripheral nerve repair: surgical applications, state of the art, and future challenges. *Crit Rev Biomed Eng* 2011;39(2):81–124
- 12 Seddon H, *Surgical Disorders of the Peripheral Nerves*. 2nd ed. New York: Churchill Livingstone; 1973 164
- 13 Sassu P, Libberecht K, Nilsson A. Nerve transfers of the forearm and hand: a review of current indications. *Plast Aesthet Res* 2015;2:195–201
- 14 Kozin SH. Nerve transfers in brachial plexus birth palsies: indications, techniques, and outcomes. *Hand Clin* 2008;24(4):363–376, v
- 15 Olivera NG, De La Red-Gallego MA, Gilbert A. Nerve transfer to restore forearm, wrist, and hand function in brachial plexus injury. In: Mahapatra AK, Midha R, Sinha S, eds. *Surgery of Brachial Plexus 2016*. 1 st ed. Delhi: Thieme Publisher; India:131–152
- 16 Colbert SH, Mackinnon SE. Nerve transfers for brachial plexus reconstruction. *Hand Clin* 2008;24(4):341–361, v
- 17 Tung TH. Nerve transfers. *Clin Plast Surg* 2014;41(3):551–559
- 18 Tötösy de Zepetnek JE, Zung HV, Erdebil S, Gordon T. Innervation ratio is an important determinant of force in normal and reinnervated rat tibialis anterior muscles. *J Neurophysiol* 1992;67(5):1385–1403
- 19 Debora Garozzo. Nerve transfer for shoulder and elbow in adult brachial plexus injuries. In: Mahapatra AK, Midha R, Sinha S, eds. *Surgery of Brachial Plexus 2016*. 1 st ed. Delhi: Thieme Publisher; India:115–129
- 20 Kotani PT, Matsuda H, Suzuki T. Trial surgical procedures of nerve transfers to avulsion injury of brachial plexus brachialis. *Excerpta Med* 1972;291:348–350
- 21 Millesi H. Indication and techniques of nerve grafting. In: Gulberman R (ed): *Operative Nerve Repair and Reconstruction*. J. B. Lippincott, Philadelphia; 1991:525–543
- 22 Narakas A. Neurotization in treatment of brachial plexus injury. In: Gulberman R(ed): *Operative Nerve Repair and Reconstruction*. J. B. Lippincott, Philadelphia; 1991:1329
- 23 Leechavengvongs S, Witoonchart K, Uerpairojkit C, Thuvasethakul P. Nerve transfer to deltoid muscle using the nerve to the long head of the triceps, part II: a report of 7 cases. *J Hand Surg Am* 2003;28(4):633–638
- 24 Oberlin C, Durand S, Belheyyar Z, Shafi M, David E, Asfazadourian H. Nerve transfers in brachial plexus palsies. *Chir Main* 2009;28(1):1–9
- 25 Bertelli JA, Kechele PR, Santos MA, Duarte H, Ghizoni MF. Axillary nerve repair by triceps motor branch transfer through an axillary access: anatomical basis and clinical results. *J Neurosurg* 2007;107(2):370–377
- 26 Gu YD, Wu MM, Zhen YL, et al. Phrenic nerve transfer for brachial plexus motor neurotization. *Microsurgery* 1989;10(4):287–289
- 27 Gu YD, Ma MK. Use of the phrenic nerve for brachial plexus reconstruction. *Clin Orthop Relat Res* 1996;( 323):119–121
- 28 Gu YD, Ma MK. Nerve transfer for treatment of root avulsion of the brachial plexus: experimental studies in a rat model. *J Reconstr Microsurg* 1991;7(1):15–22
- 29 Chuang DC, Lee GW, Hashem F, Wei FC. Restoration of shoulder abduction by nerve transfer in avulsed brachial plexus injury: evaluation of 99 patients with various nerve transfers. *Plast Reconstr Surg* 1995;96(1):122–128
- 30 Sungpet A, Suphachitwong C, Kawinwonggowith V. Restoration of shoulder abduction in brachial plexus injury with phrenic nerve transfer. *Aust N Z J Surg* 2000;70(11):783–785
- 31 Xu WD, Gu YD, Xu JG, Tan LJ. Full-length phrenic nerve transfer by means of video-assisted thoracic surgery in treating brachial plexus avulsion injury. *Plast Reconstr Surg* 2002;110(1):104–109, discussion 110–111
- 32 Ferraresi S, Garozzo D, Basso E, Maistrello L, Lucchin F, Di Pasquale P. The medial cord to musculocutaneous (MCMc) nerve transfer: a new method to reanimate elbow flexion after C5-C6-C7-(C8) avulsive injuries of the brachial plexus—technique and results. *Neurosurg Rev* 2014;37(2):321–329, discussion 329
- 33 Tsai YJ, Su FC, Hsiao CK, Tu YK. Comparison of objective muscle strength in C5-C6 and C5-C7 brachial plexus injury patients after double nerve transfer. *Microsurgery* 2015;35(2):107–114
- 34 Maldonado AA, Bishop AT, Spinner RJ, Shin AY. Five operations that give the best results after brachial plexus injury. *Plast Reconstr Surg* 2017;140(3):545–556
- 35 Mackinnon SE, Novak CB, Myckatyn TM, Tung TH. Results of reinnervation of the biceps and brachialis muscles with a double fascicular transfer for elbow flexion. *J Hand Surg Am* 2005;30(5):978–985